

European Journal of Health Sciences (EJHS)



**EVALUATION OF FUNGAL SINUSITIS ON COMPUTED
TOMOGRAPHY AND ITS CORRELATION WITH ENDOSCOPY
AND HISTOPATHOLOGY FINDINGS**

Ameer Hamza, Qainat Ishfaq
Alisha Afzal, Aneesa Shafeeq
Muhammad Junaid, Dr Sara Maryum
Dr Anwarul Haq, Yousaf Gillani



EVALUATION OF FUNGAL SINUSITIS ON COMPUTED TOMOGRAPHY AND ITS CORRELATION WITH ENDOSCOPY AND HISTOPATHOLOGY FINDINGS

Ameer Hamza, Qainat Ishfaq, Alisha Afzal, Aneesa Shafeeq, Muhammad Junaid

Undergraduate Students: The University of Lahore

Supervisor: Dr Sara Maryum

Co-supervisor: Dr Anwarul Haq

Data analysis: Yousaf Gillani

E-mail: myfluffy123123@gmail.com

Abstract

Purpose: To evaluate fungal sinusitis on computed tomography and its correlation with endoscopy and histopathology findings.

Methodology: A comparative cross sectional analytical study was conducted at a tertiary care in Lahore. During four months of research period 138 patients were observed. CT scan was performed routinely on 128 slice CT machine by Siemens Germany Ltd having slice thickness of 3 mm, reconstructions at 0.75 mm in coronal and sagittal planes. Scanning parameters included 190 mA, 120 KV and tube rotation time of 0.5 s. Preoperative evaluation by CT was mandatory for all patients undergoing functional endoscopic sinus surgery (FESS). The findings of endoscopy and histopathology were also collected in all those cases when the investigation was done. The data was then analysis by using SPSS version 25.

Findings: Out of 138 patients, 63 females and 75 males were observed. 80 were affected unilaterally (58%) and 58 were affected bilaterally (42%). 111 patients showed sinus expansion (80.4%) and 84 patients showed extra sinus expansion (60.9%). 106 patients were diagnosed on CT (76.8%). All those 106 were sent for endoscopy, out of which 94 patients (68.1%) were affected on endoscopy. But the tissue cultures of 106 patients after endoscopy were sent for histopathology that confirmed 96 patients (69.6%) were affected with fungal sinusitis.

Unique contribution to theory, practice and policy: CT scan is very sensitive for detecting fungal sinusitis. It is a non-invasive and easily available procedure that will help in the early diagnosis on fungal sinusitis. But it is nonspecific as it does not give the confirmation about the nature of sinusitis.

Key words: *Computed Tomography, Endoscopy, Histopathology.*

INTRODUCTION

Fungal rhinosinusitis is encountered in 10% of the patients having chronic rhinosinusitis. Commonly affected age group is the third decade with equal sex ratio¹. Chronic fungal sinusitis is more prevalent in the female than male and associated with worsened symptomatology². Acute invasive fungal sinusitis is a rapidly progressing and most lethal form of fungal sinusitis, with a reported mortality of 50 - 80%. Up to 80% of invasive fungal infections in this group are caused by fungi belonging to the order Zygomycetes, such as *Rhizopus*, *Rhizomucor*, *Absidia* and *Mucor* and infection by these organisms is sometimes termed zygo-mycosis³. Granulomatous invasive fungal sinusitis is more commonly found in the Pakistan, India and Sudan⁴. Sinus fungal ball (SFB) accounts for approximately 40 % of patients with fungal rhinosinusitis⁵. Invasive acute fungal rhinosinusitis (IAIFR) carries a high mortality rate⁶.

Fungal rhinosinusitis is classified into two categories invasive disease and non-invasive diseases, based on the histopathological evidence of a fungus penetrating the host tissues (mucosa, blood vessels, or bone)⁴. Invasive fungal rhinosinusitis includes acute fulminant invasive fungal sinusitis, granulomatous invasive fungal sinusitis, and chronic invasive fungal sinusitis, whereas, non-invasive fungal rhinosinusitis includes allergic fungal rhinosinusitis and sinus fungus ball (SFB). Invasive paranasal fungal sinusitis may be observed in immunodeficient hosts, whereas, the non-invasive form may be observed in immunocompetent patients⁷. Acute and chronic rhinosinusitis is a frequent infection in the immunocompromised patients. These patients are prone to develop invasive fungal sinusitis and complications of sinusitis⁸. Acute invasive fungal rhinosinusitis (AIFRS) is a lethal form of sinusitis with high morbidity and mortality, in immunocompromised patients and it needs a rapid diagnosis and treatment. A rapid and accurate diagnosis is crucial for the timely and effective treatment and prevention of complications⁹.

Literature highlights the importance of CT scan in the diagnosis of fungal sinusitis. CT is superior in delineating the fine bone structures of the infundibular complex, orbital lamina, orbital floor, and cribriform lamina. Thus CT is more effective as a preoperative diagnostic technique while planning a functional endoscopic sinus surgery. Therefore CT is regarded as the gold standard in paranasal sinus imaging¹⁰. There is always a dilemma as the most common CT features are nonspecific mucosal hypertrophy and in some cases hyperdense attenuation is not seen, as in 75% cases. Understanding the different types of fungal sinusitis and knowing their radiologic features allows the radiologist to play a crucial role in alerting the clinician to use appropriate diagnostic techniques for confirmation. Considering histopathological diagnosis as the gold standard, fungal sinusitis could be correctly diagnosed on CT with high accuracy³. However the presence of immune compromised status, bone erosion, extension beyond sino-nasal cavities in conjunction with endoscopy findings can clinch the diagnosis in all cases. In chronic invasive fungal sinusitis, inhaled fungal organisms are deposited in the nasal passage³.

CT scan is a noninvasive procedure with no pain and the results would give us a major clue regarding to fungal sinusitis. Generally, a biopsy is safe and causes minimal injury. Complications that are made from biopsies include bleeding and infection. This study assess the evaluation of fungal sinusitis on computed tomography and its correlation with endoscopy and histopathology findings for better and early diagnosis and management of fungal sinusitis.

RESULTS

Out of 138 patients, 63 females and 75 males were observed. 80 were affected unilaterally (58%) and 58 were affected bilaterally (42%). 111 patients showed sinus expansion (80.4%) and 84 patients showed extra sinus expansion (60.9%). 106 patients were diagnosed on CT (76.8%). All those 106 were sent for endoscopy, out of which 94 patients (68.1%) showed infection on endoscopy . But the tissue cultures of 106 patients after endoscopy were sent for histopathology, that confirmed 96 patients (69.6%) were affected with fungal sinusitis.

Gender Frequency Table.

	Frequency	Percent
Females	63	45.7
males	75	54.3
Total	138	100.0

Unilateral and Bilateral Frequency

		Frequency	Percent
Valid	bilateral	58	42.0
	unilateral	80	58.0
	Total	138	100.0

Table 2: This table shows the unilateral and bilateral percentages of the patients .

Gender and Unilateral and Bilateral Cross tabulation

		Bi	uni	Total
gender	Female	24	39	63
	male	34	41	75
Total		58	80	138

Table 3: This table shows that out of 63 females, 39 were unilateral and 24 were bilateral. Out of 75 males, 41 were unilateral and 34 were bilateral.

Graph Bars of Sinus Expansion and Extra Sinus Expansion.

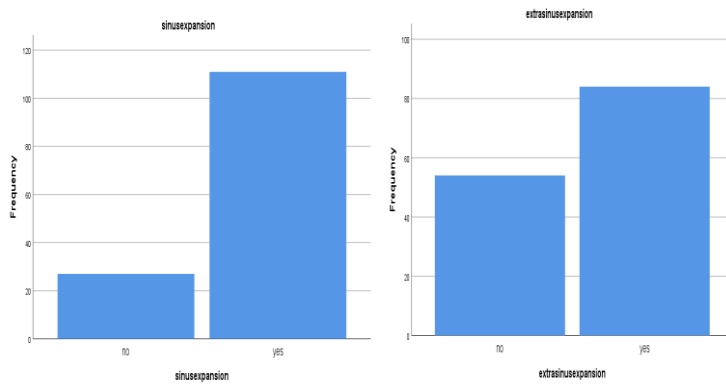


Figure 1: These figures show the cumulative percentages of patients having sinus expansion and extra sinus expansion.

Computed Tomography Diagnosis

	Frequency	Percent
no	32	23.2
yes	106	76.8
Total	138	100.0

Table 4: Following table show the patients who diagnosed having fungal sinusitis on CT. 106 out of 138 were diagnosed with affection of Fungal Sinusitis.

Endoscopy Diagnosis

	Frequency	Percent
no	44	31.9
yes	94	68.1
Total	138	100.0

Table 5: Following table show the patients who diagnosed having fungal sinusitis on endoscopy. 94 out of 106 were diagnosed with affection of Fungal Sinusitis when their biopsy was taken and studied after CT.

Histopathology Diagnosis.

	Frequency	Percent
no	42	30.4
yes	96	69.6
Total	138	100.0

Table 6: Following table show the patients who diagnosed having fungal sinusitis on histopathology. 96 out of 106 were diagnosed with affection of Fungal Sinusitis when their culture was studied after CT and endoscopy procedure.

**Ct diagnosis * endoscopy diagnosis
 Cross tabulation**

		Endoscopy diagnosis		Total
		no	yes	
Ct diagnosis	no	32	0	32
	yes	12	94	106
Total		44	94	138

**Ct diagnosis * histopathology diagnosis
 Cross tabulation**

		Histopathology diagnosis		Total
		no	yes	
Ct diagnosis	no	32	0	32
	yes	10	96	106
Total		42	96	138

Table 7 and Table 8 : These two tables show the cross tabulation of CT scan with endoscopy and histopathology. In these table the frequency of CT patients who were sent for endoscopy and histopathology is tabulated.

138 patients were observed in this whole study. Out of these 138 patients, 106 were diagnosed on CT and for the further evaluations they were sent for endoscopy. 94 patients showed endoscopy findings positive but the fungal hypae cultural test of all 106 patients was performed. 96 patients were confirmed to have fungal sinusitis when they were observed on histopathology.

DISCUSSION

On imaging hyperdense attenuation with bony sclerosis and expansion is the most important clue to diagnosis. There is usually calcification in the fungal hyphae³. This study showed that all of the patients who underwent for the CT procedure had absence of air fluid level and 111 patients (80.4%) had sinus expansion. Extra expansion of sinus was present in 84 patients (60.9%). All patients showed soft tissue attenuation on CT scan. Results were compared with the similar study conducted by Gupta K and Saggar K, in their study 16 patients were observed. Out of total 16 patients, 12 showed immuno-compromised status and had infection with mucormycosis. Out of 12, 9 patients (75%) showed extension of disease beyond the sinonasal cavities and 4 (33.3%) showed evidence of bone destruction. All patients showed soft tissue attenuation with hyperdense areas on CT scan.³ Ninety six patients (69.6%) were proved to be have fungal sinusitis on histopathology in the above study. Fifteen patients (93%) proved to have fungal sinusitis on histopathology³. In their study they concluded that fungal sinusitis could be correctly diagnosed on CT with high accuracy and understanding the different CT findings of fungal sinusitis allows the radiologist to play a crucial role in the diagnosis and prompt treatment.³

On the CT based findings, eighty patients were have unilateral sinus opacification (58%) and fifty eight patients were have bilateral sinus involvement (42%). A similar study was conducted by Wang X, Dong D, Cheng J, Fan X, Zhao Y, and their study showed that according to CT based findings 27 patients (42.2%) had single sinus opacification and bilateral involvement was present in 8 patients (12.5%).⁵

Above study showed that the patient who had CT procedure shower no air fluid level. They have inflammatory cells and soft tissues were affected. When compared with a study that was conducted by Chen JC and Ho CY, their study included 96 Sinus Fungal Ball patients and 72 unilateral chronic rhinosinusitis patients. Six major CT features of fungal sinusitis, including the presence of a diffuse homogeneous mass of moderate attenuation, expansion of the sinus with thinning and erosion of the bony margins, bone sclerosis and remodelling, absence of an air–fluid level, and calcific hyper attenuation, have been reported. They concluded particularly calcification and erosion of the inner wall of the sinus, increase the diagnostic accuracy of CT for sinus fungal ball and this ensures that the patient receives appropriate treatment.⁷

In a study conducted by Bhattacharyya N, reported that preoperative computed tomography (CT) stage predicts degree of symptom improvement after endoscopic sinus surgery (ESS). He concluded CT scan is widely accepted as an accurate diagnostic tool for chronic rhinosinusitis.¹⁸ Above study also showed CT predict the early stages of fungal sinusitis as 76.8% patients showed symptoms of fungal sinusitis on early diagnostic procedure.

Out of 138 patients, 63 females and 75 males were observed. 80 were affected unilaterally (58%) and 58 were affected bilaterally (42%). 111 patients showed sinus expansion (80.4%) and 84 patients showed extra sinus expansion (60.9%). 106 patients were diagnosed on CT (76.8%). All those 106 were sent for endoscopy, out of which 94 patients (68.1%) showed infection on endoscopy. But the tissue cultures of 106 patients after endoscopy were sent for histopathology that confirmed 96 patients (69.6%) were affected with fungal sinusitis. Considering Histopathology findings are gold standard for the confirmation of fungal sinusitis³ Our current

study showed that CT scan can give us the clue regarding fungal sinusitis but its result should always be confirmed with biopsy. CT images help in guiding sinus surgical procedures¹⁰.

References

- 1- Karthikeyan P, Coumare VN. Incidence and presentation of fungal sinusitis in patient diagnosed with chronic rhinosinusitis. *Indian Journal of Otolaryngology and Head & Neck Surgery*. 2010 Oct 1;62(4):381-5.
- 2- Azar A, Rank MA, Zarka MA, Chang YH, Lai D. Gender-specific differences in serum immunoglobulin E levels and prevalence of fungus in sinonasal tissue noted in patients with chronic rhinosinusitis who underwent endoscopic sinus surgery. *American journal of rhinology & allergy*. 2017 Nov;31(6):370-5.
- 3- Gupta K, Saggar K. Analysis of computed tomography features of fungal sinusitis and their correlation with nasal endoscopy and histopathology findings. *Annals of African medicine*. 2014;13(3):119-20.
- 4- Mhurchu EN, Ospina J, Janjua AS, Shewchuk JR, Vertinsky AT. Fungal rhinosinusitis: a radiological review with intraoperative correlation. *Canadian Association of Radiologists Journal*. 2017 May 1;68(2):178-86.
- 5- Wang X, Dong D, Cheng J, Fan X, Zhao Y. Relationship between biofilms and clinical features in patients with sinus fungal ball. *European Archives of Oto-Rhino-Laryngology*. 2015 Sep 1;272(9):2363-9.
- 6- Middlebrooks EH, Frost CJ, De Jesus RO, Massini TC, Schmalfuss IM, Mancuso AA. Acute invasive fungal rhinosinusitis: a comprehensive update of CT findings and design of an effective diagnostic imaging model. *American Journal of Neuroradiology*. 2015 Aug 1;36(8):1529-35.
- 7- Chen JC, Ho CY. The significance of computed tomographic findings in the diagnosis of fungus ball in the paranasal sinuses. *American journal of rhinology & allergy*. 2012 Mar;26(2):117-9.
- 8- Tzelnick S, Soudry E. Rhinosinusitis in solid organ transplant recipients: analysis of 4562 transplanted patients. *American journal of rhinology & allergy*. 2019 Jan;33(1):56-61.
- 9- Crist H, Hennessy M, Hodos J, McGinn J, White B, Payne S, Warrick JI. Acute Invasive Fungal Rhinosinusitis: Frozen Section Histomorphology and Diagnosis with PAS Stain. *Head and neck pathology*. 2018 Sep 12:1-9.
- 10- Zheng Y, Zhao Y, Lv D, Liu Y, Qiao X, An P, Wang D. Correlation between computed tomography staging and quality of life instruments in patients with chronic rhinosinusitis. *American journal of rhinology & allergy*. 2010 Jan;24(1):e41-5.

- 11- Alastruey-Izquierdo A, Cadranel J, Flick H, Godet C, Hennequin C, Hoenigl M, Kosmidis C, Lange C, Munteanu O, Page I, Salzer HJ. Treatment of chronic pulmonary aspergillosis: current standards and future perspectives. *Respiration*. 2018;96(2):159-70.
- 12- Dai LB, Zhou SH, Ruan LX, Zheng ZJ. Correlation of computed tomography with pathological features in angiomatous nasal polyps. *PloS one*. 2012 Dec 31;7(12):e53306.
- 13- Starkey J, Moritani T, Kirby P. MRI of CNS fungal infections: review of aspergillosis to histoplasmosis and everything in between. *Clinical neuroradiology*. 2014 Sep 1;24(3):217-30.
- 14- Ryan MW. Allergic fungal rhinosinusitis. *Otolaryngologic clinics of North America*. 2011 Jun 1;44(3):697-710.
- 15- Seo YJ, Kim J, Kim K, Lee JG, Kim CH, Yoon JH. Radiologic characteristics of sinonasal fungus ball: an analysis of 119 cases. *Acta Radiologica*. 2011 Sep;52(7):790-5.
- 16- Smith T. British Medical Association complete family health guide. Dorling Kindersley; 2000 Sep 1.
- 17- Mitchell RS, Kumar V. Robbins basic pathology. Saunders.
- 18- Bhattacharyya N. Radiographic stage fails to predict symptom outcomes after endoscopic sinus surgery for chronic rhinosinusitis. *The Laryngoscope*. 2006 Jan;116(1):18-22.
- 19- Kanwar SS, Mital M, Gupta PK, Saran S, Parashar N, Singh A. Evaluation of paranasal sinus diseases by computed tomography and its histopathological correlation. *Journal of Oral and Maxillofacial Radiology*. 2017 May 1;5(2):46.