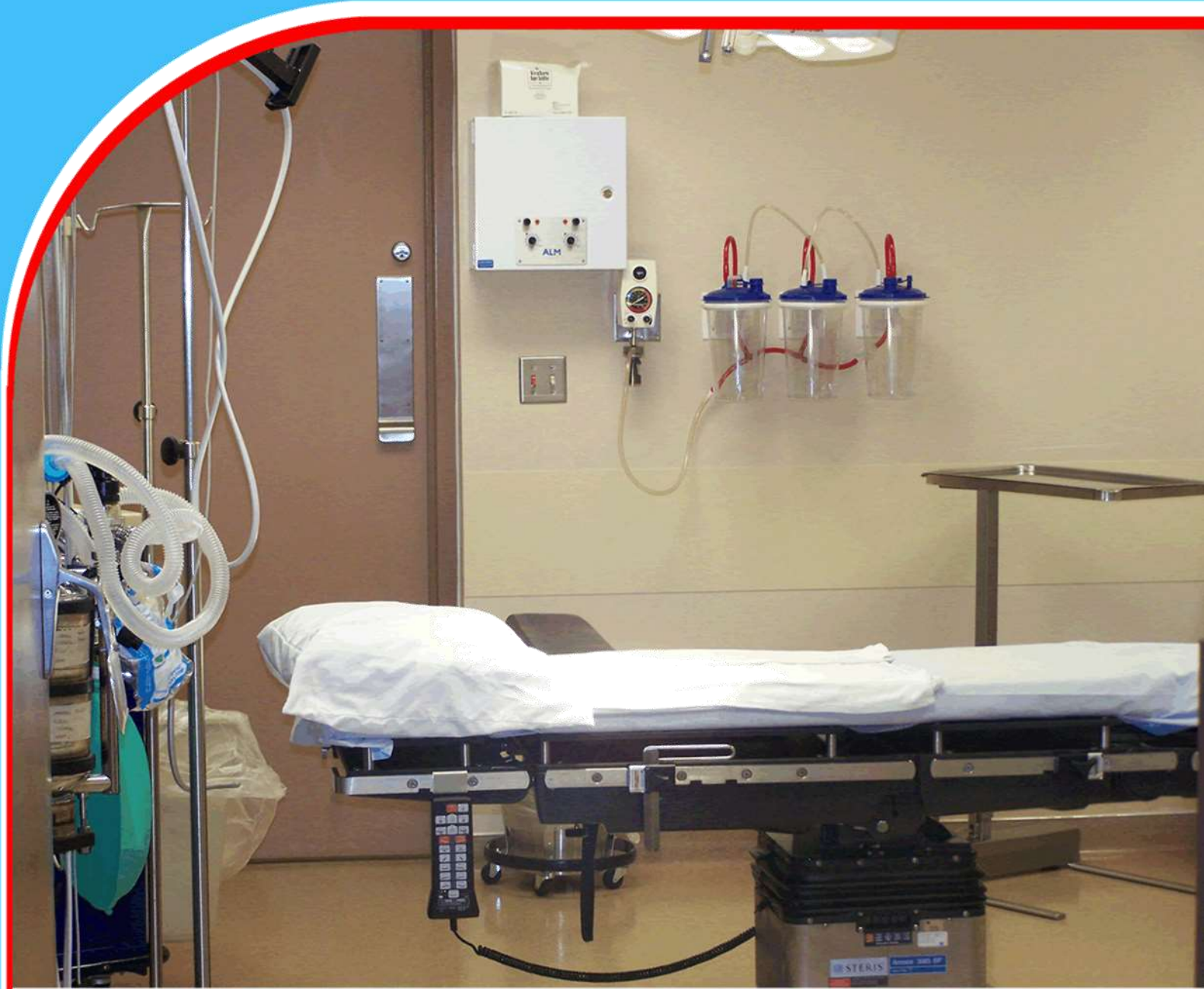

American Journal of Health, Medicine and Nursing Practice (AJHMPN)




Trichobezoar, An Unusual Cause of Small Bowel Obstruction in Pediatrics Age Group

Farooque Ahmed Khan, Ammar Almashhadi, and Nadeem Haider



Trichobezoar, An Unusual Cause of Small Bowel Obstruction in Pediatrics Age Group

 **Farooque Ahmed Khan^{1*}, Ammar Almashhadi², and Nadeem Haider³**
¹Senior Specialist General Surgeon, Sheikh Khalifa Medical City, Ajman, UAE
²Consultant, Pediatric Surgeon, Sheikh Khalifa Medical City, Ajman, UAE
³Consultant, Pediatric Surgeon, Sheikh Khalifa Medical City, Ajman, UAE



Article History

Submitted 27.09.2023 Revised Version Received 01.10.2023 Accepted 27.10.2023

Abstract

Purpose: Trichobezoar, is a ball of swallowed hair, which is usually found in the stomach with a possibility of extension to the duodenum. As the tail can propagate to the small intestine, it is also given the name “Rapunzel syndrome”. The primary aim of this paper is to highlight an uncommon cause of intestinal obstruction in children and to share our experience of management in one of the youngest children reported in the literature. The secondary aim is to share a review of literature on this topic.

Methodology: The hospital case notes of our patient were thoroughly reviewed and detailed history was confirmed with the family. Radiological imaging was discussed with a senior radiologist. We report a 3-year-old African child who presented to our emergency department with

signs and symptoms of acute intestinal obstruction.

Findings: After a thorough review of the literature, we document that ours is the second report of trichobezoar causing small intestinal obstruction in a 3-year-old child. At laparotomy, a 25 cm long trichobezoar was removed from the ileum with an enterotomy.

Recommendations: Although it is a rare and unusual cause of isolated small bowel obstruction but with prompt diagnosis and timely intervention the outcome is excellent.

Keywords: *Trichobezoar, Trichotillomania, Small Bowel Obstruction, Child.*

1.0 INTRODUCTION

A 'Bezoar' is a tightly packed collection of partially digested or undigested material that most commonly occurs in the stomach but can be found in the small intestine and rarely in the colon. The term is derived from the Arabic word "badzehr" meaning 'antidote'. Since bezoars formed in the stomach of certain animals especially ruminants, they were traditionally used in ancient times as cures for poison (1,2). Bezoars are of various types namely, Phytobezoar (plant material), Trichobezoar (hair), Lithobezoar (stone), Lactobezoar (milk), Pharmacobezoar (tablets), and Plasticobezoar (plastic) (2). The most common type is the phytobezoar, while trichobezoar accounts for less than 6% of all cases of bezoars found in humans.

Trichobezoar was first described in 1779 in a 16-year-old boy. It is common in young (2nd and 3rd decade) females with a psychiatric disorder and seldom found in the pediatric age group. Trichobezoar formation is strongly associated with Trichotillomania (hair pulling) and Trichophagia (hair eating) but sometimes it can develop when the patient eats the hair of their family members and even toys (3). Human hair is resistant to digestion and peristalsis due to its smooth surface. Thus, they accumulate in the mucosal folds of the stomach. In due course, ongoing ingestion of hair leads to impaction, and together with mucous and food, this results in the development of a trichobezoar. Unrecognized, it continues to grow in size and weight due to continued ingestion of hair. Presenting symptoms include abdominal pain, palpable mass, nausea, vomiting, weight loss, constipation, and sometimes hematemesis.

The majority of trichobezoars are confined to the stomach. They can sometimes extend into the small intestine or even the colon. This condition is known as the Rapunzel syndrome, and it was first described by Vaughan et. Al. in 1968 (4,5). Most trichobezoars may not be diagnosed in their early stage due to their nonspecific presentation or even lack of symptoms. Owing to late diagnosis and treatment there may be several complications, such as gastric mucosal erosion, ulceration, and perforation of the stomach and small intestine (14,15). Intussusception, obstructive jaundice, protein-losing enteropathy, and pancreatitis are some other complications (16,17). Death has been reported as a complication of unrecognized trichobezoar in the literature (6,7). With the advent of minimally invasive surgery and endoscopic mechanical and laser fragmentation techniques, some authors have questioned the necessity of laparotomy. They prefer newer techniques for Trichobezoar retrieval (8,9,10)

2.0 CASE REPORT

A 3-year-old girl not known to have any comorbidities attended our emergency department for the evaluation of colicky abdominal pain of 3 days duration. The pain was accompanied by diarrhea, non-projectile vomiting, and decreased oral intake.

No History of Rectal Bleeding or Urinary Symptoms

Physical examination revealed an irritable, sick-looking, dehydrated, and listless African child. She had unremarkable vital signs and weighed 13.3 kg. She had a normocephalic head with curly hair without any sign of Alopecia. No abnormality was detected on respiratory or cardiovascular examination. Neurological examination was unremarkable, and she was developmentally appropriate. There was generalized distention of the abdomen with tenderness all over. There was no hepatosplenomegaly or palpable mass, and her bowel sounds were sluggish. She was anemic (hemoglobin 9.9 g/dL) with a raised C-Reactive Protein (71.26 g/L). She was also hyponatremic

with a sodium of 127 meq/L. Renal function was normal. An abdominal ultrasound was inconclusive. A Plain abdominal x-ray and CT scan of the abdomen suggested distal small bowel obstruction with a possibility of intussusception or a foreign body impaction. (fig. 1-4)

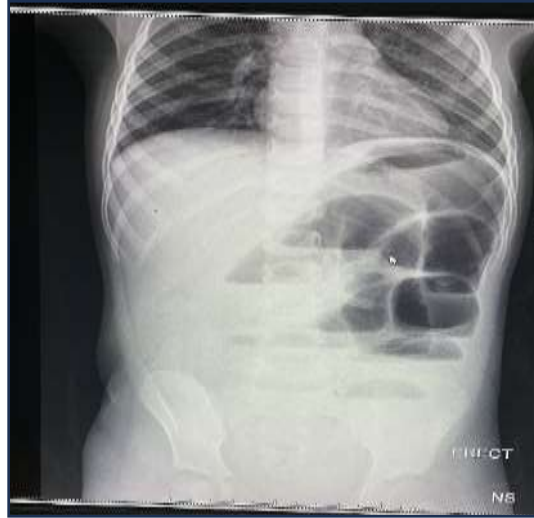

Figure 1: Plain Abdominal X-Ray Showing Dilated Loops of Small Bowel with Multiple Air Fluid Level and Absent Air In

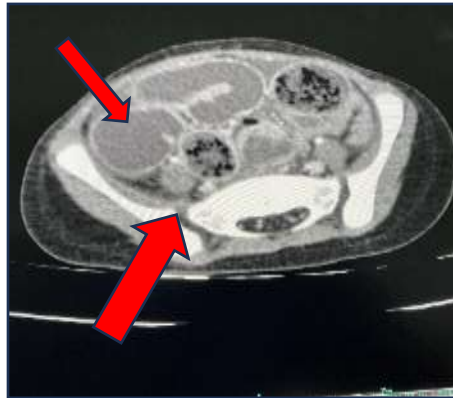


Figure 2

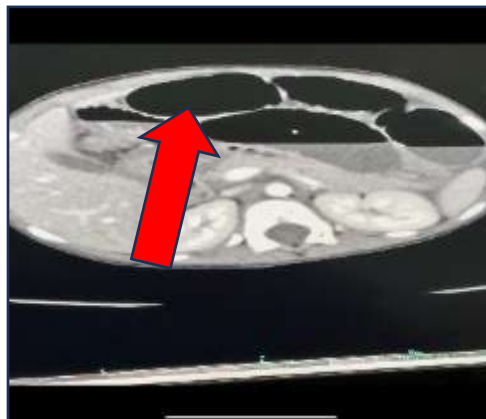


Figure 3

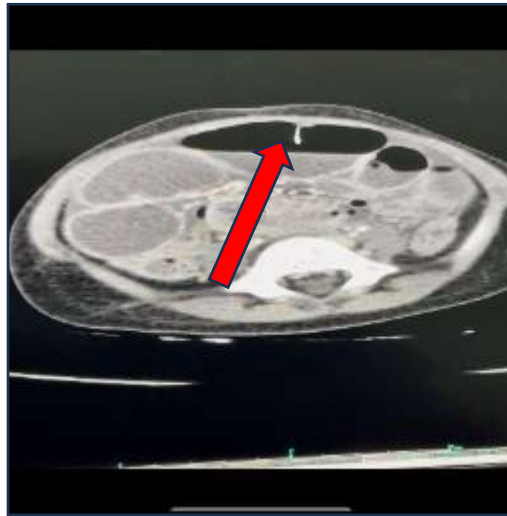


Figure 4

At emergency laparotomy an obvious intraluminal ileal mass (fig. 5) was found along with significant ascites and dilated small bowel loops.

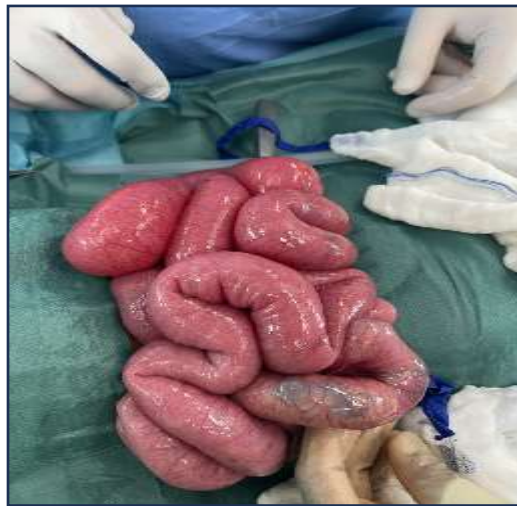

Figure 5: Intraoperative Photograph Showing Intraluminal Mass as Well as Distended Proximal Bowel Loops

A 5 cm longitudinal enterotomy was made on the antimesenteric border just proximal to the intraluminal mass (fig. 6). We removed 25 cm trichobezoar (fig. 8). The enterotomy was repaired with simple interrupted single layer extra mucosal sutures and the abdominal wound closed in the usual fashion. Upon questioning the parents, it was revealed that the child had suffered from intermittent abdominal pain since the age of 2-years and frequently ingested hair, soil, and paint at home. Psychiatric help had not been sought. The patient had an uneventful recovery and was discharged on the 6th postoperative day. She was followed up in OPD after two weeks and was doing fine. A psychiatrist consultation was requested for ongoing counseling regarding the underlying behavioral issue.

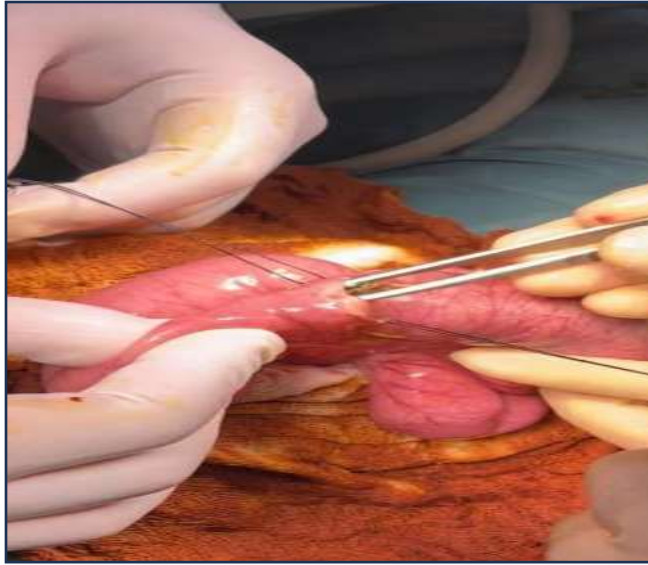


Figure 6: A longitudinal enterotomy over the antimesenteric border for retrieval of the trichobezoar

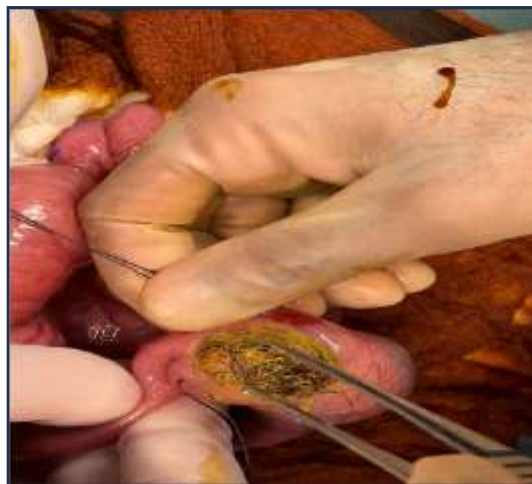

Figure 7: Closeup Photograph Showing Retrieval of Trichobezoar

Discussion

Trichotillomania and trichophagia are disorders that frequently present together and are also associated with obsessive-compulsive disorder or another behavioral abnormality. Trichotillomania was first described in 1889 and the incident is around 1 in 2000 general population. Over 80% of trichobezoars occur before the age of 30 years., and more than 90 % have been in girls It involves the pulling of hair from the scalp resulting in alopecia in many cases. Eyelashes, eyebrows, and axilla are also potentially susceptible. (3). Only 30% of these patients swallow the pulled-out hair and of those that do, only 1% will eventually develop a trichobezoar requiring surgical intervention. (3) The condition is more likely to be benign and self-limiting if the onset is before the age of 7. These account for about 14% of the cases of Trichotillomania. The disease is more likely to become chronic and associated with various other psychiatric

disorders such as depression, anxiety, and obsessive-compulsive disorder in 10% of cases when the onset occurs during adolescence or adulthood (3). Repeated and long-standing ingestion of hair results in accumulated strands of hair in the gastric rugae because there is insufficient friction for them to be propelled by peristalsis (11). The smooth and slippery surface of trichobezoar helped by entrapped food particles and mucous further impedes its passage through the pylorus (2).

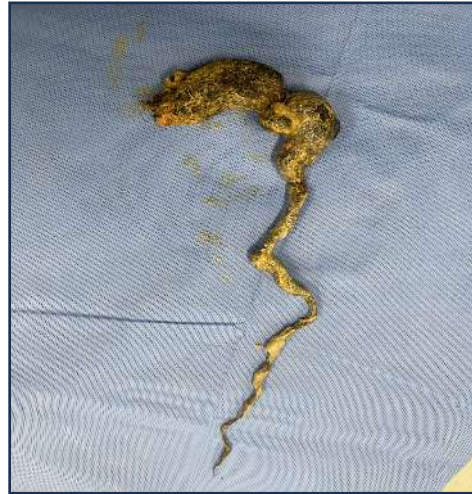

Figure 8: 25 Cm Trichobezoar Removed from Ileum

The Rapunzel syndrome was described in 1968 after the famous German fairytale character (13). Depending on the size, location, and chronicity there are several complications that can arise from trichobezoar which have been mentioned in the introduction above but one complication that was present in our patient, Anemia is worth mentioning here. It results from iron malabsorption and chronic ulceration. Acute hematemesis is present in up to 6% of cases (13). If left undiagnosed, 26% of patients will have acute bowel obstruction and 18% will suffer from peritonitis from visceral perforation (18) Once a trichobezoar is diagnosed the primary management involves its retrieval. Medical treatment and enzymatic degradations although attractive because of their noninvasiveness have been reported ineffective (19,20)

In the literature, several treatment options are proposed. These include removal by conventional laparotomy, laparoscopy, and endoscopy. Laparotomy is the most performed procedure with a 99% success rate (1). Since these patients usually present very late and with a large intraluminal mass, a total laparoscopic approach fails in most cases especially in children and small adults owing to limited working space. However, the successful laparoscopic management of a large gastric trichobezoar in a 12-year-old girl has been described by Bustaus et al. (21). Neerasawa et al. (22) were the first to report on laparoscopic retrieval of a trichobezoar in the yr.1998. Numerous reports of laparoscopic removal attempts have been published since then.

Palanivelu et al (8) reported the laparoscopic retrieval of concomitant gastric and ileal trichobezoar. However, these were removed through a mini-laparotomy. In a review by Gotter et al (14), laparoscopy was successful in 75% of the cases with no complications. Horish et al on the other hand reported a 55% conversion rate to an open procedure after a laparoscopic approach.

Successful laparoscopic removal requires significantly longer operating time in comparison to laparotomy. With laparoscopy, the process of careful examination of the entire digestive system is far more challenging. The risk of spilling contaminated hair fragments into the abdominal cavity makes the laparoscopic approach even less attractive. Due to the rarity of trichobezoars, it may be difficult to master the method for laparoscopic removal and inspection of the entire intestine. If successful, endoscopic removal would be the most alluring option.

Endoscopic retrieval has been described but is only successful in around 5% of cases of gastric trichobezoar. The first successful endoscopic, trichobezoar removal report was one that was a rather small mass, weighing only 55 g. (25). RR Gotter et al. (14) and many others failed to retrieve trichobezoar endoscopically with or without fragmentation due to its size, density, and hardness. (8, 9, 23, 27, 28, 29, 30). In addition, pressure ulceration, esophagitis, and even esophageal perforation may occur since the endoscope must be introduced numerous times to remove all fragments. (24, 31). After being fragmented or repeatedly manipulated, a large trichobezoar may migrate through the pylorus and cause intestinal obstruction. (32) It can be challenging to inspect the intestinal tract for satellites using an endoscope.

Dissolution therapy using lipase, cola, papain, and gastric lavage has been tried but the size and density of trichobezoars have limited the success of these methods (13,34,35). Open surgery therefore remains the current mainstay of treatment for this condition. Recurrent trichobezoar has been reported and usually occurs in patients who have not had adequate psychiatric evaluation and follow-up. There are no robust guidelines for the long-term management of trichotillomania or for patients after trichobezoar extraction. Achieving long-term counseling and undergoing regular psychological evaluations are essential in preventing future occurrences.

Trichotillomania and trichophagia are rare conditions. Only 1-2 people per million are affected. To the best of our knowledge, our case is the youngest case of trichotillomania and trichophagia resulting in acute small bowel obstruction without a trace in the stomach in a female child. Before us, Michele Van Hal et al-2022 (36) had reported a case like ours in a 3-year-old African American boy who presented to the emergency department with abdominal pain, decreased oral intake, and constipation for the past 3 days. He was irritable and in moderate distress but appeared ill and non-toxic (like ours). He was noted to have curly hair without any signs of hair loss. His respiratory and cardiovascular examination was normal, just like our case.

Abdominal findings were similar to our patient (generalized distention with tenderness all over but more on the left side with no hepatosplenomegaly or palpable mass and sluggish bowel sounds). Their patient had mild hypoalbuminemia whilst our patient was anemic and hyponatremic with elevated CRP. The ultrasound in the boy's case revealed moderate ascites and mildly dilated fluid-filled bowel loops while our ultrasound was inconclusive. CT finding was almost similar in both cases. The final diagnosis was acute small bowel obstruction in both cases. They removed the trichobezoar from the jejunum whereas we removed it from the ileum. Thus, our patient represents a highly unusual variant of trichobezoar at a very young age and in an uncommon location. In addition, the fact that she was only 3 years of age with normal intelligence and had no known history of parental neglect, social stressors or mental retardation and without sign of alopecia makes this diagnosis even more unexpected and challenging.

3.0 CONCLUSION AND RECOMMENDATIONS

Trichobezoar causing isolated acute small bowel obstruction in a 3-year-old child is an exceedingly rare condition. It has only been described in the literature once before. Even in the absence of trichotillomania, it should still be amongst the differential diagnoses in children with abdominal pain and altered bowel habits after the more common causes have been excluded. Laparotomy remains one of the most popular approaches despite some of the other more novel options.

Source of Support

none

Conflict of Interest

none.

REFERENCES

1. Wang Z, Cao F, Liu D, Fang Y, Li F. The diagnosis and treatment of Rapunzel syndrome. *Acta Radiol Open*. 2016; 5(11): 2058460115627660.
2. Blejc Novak A, Zupancic Z, Plut D, Gvardijancic D, Homan M. Rapunzel syndrome: a rare form of trichobezoar in the stomach with some extension into the small intestine. *Acta Dermatovenerol Alp Pannonica Adriat*. 2018; 27(3): 155-157.
3. Frey AS, McKee M, King RA, Martin A. Hair apparent: Rapunzel syndrome. *Am J Psychiatry*. 2005; 162(2): 242-248.
4. Vaughan ED Jr, Sawyers JL, Scott HW Jr (1968) The Rapunzel syndrome. An unusual complication of intestinal bezoar. *Surgery* 63:339–343.
5. Naik S, Gupta V, Rangole A, Chaudhary AK, Jain P, Sharma AK (2007) Rapunzel syndrome reviewed and redefined. *Dig Surg* 24:157–161.
6. Ventura DE, Herbella FAM, Schettini ST, Delmonte C (2005) Rapunzel syndrome with a fatal outcome in a neglected child. *J Pediatr Surg* 40:1665–1667.
7. Mehta MH, Patel RV (1992) Intussusception and intestinal perforations caused by multiple trichobezoars. *J Pediatr Surg* 27:1234–1235.
8. Palanivelu C, Rangarajan M, Senthilkumar R, Madankumar MV (2007) Trichobezoars in the stomach and ileum and their laparoscopy-assisted removal: a bizarre case. *Singapore Med J* 48:37–39.
9. Michail S, Nanagas V, Mezoff AG (2008) An unusual cause of postfundoplication vomiting. *J Pediatr Surg* 43:E45–E47.
10. Hernandez-Peredo-Rezk G, Escarcega-Fujigaki P, Campillo-Ojeda Z, Sanchez-Martinez ME, Rodriguez-Santibanez MA, del Angel-Aguilar A et al (2009) Trichobezoar can be treated laparoscopically. *J Laparoendoscop Adv Surg Tech A* 19:111–113.
11. Reisfeld R, Dammert W, Simpson JS. Trichobezoar: an uncommon pediatric problem. *Can J Surg*. 1978; 21(3): 251-252.
12. Czerwinska K, Bekiesinska-Figatowska M, Brzewski M, Gogolewski M, Wolski M. Trichobezoar, rapunzel syndrome, tricho-plaster bezoar - a report of three cases. *Pol J Radiol*. 2015; 80: 241-246.
13. Garcia-Ramirez BE, Nuno-Guzman CM, Zaragoza-Carrillo RE, Salado-Renteria H, Gomez-Abarca A, Corona JL. Small-bowel obstruction secondary to ileal trichobezoar in a patient with Rapunzel syndrome. *Case Rep Gastroenterol*. 2018; 12(3): 559-565.
14. Gorter RR, Kneepkens CM, Mattens EC, Aronson DC, Heij HA. Management of trichobezoar: Case report and literature review *Pediatr Surg Int*. 2010;26:457–63.
15. Ripollés T, García-Aguayo J, Martínez MJ, Gil P. Gastrointestinal bezoars: Sonographic and CT characteristics *AJR Am J Roentgenol*. 2001;177:65–9.
16. Ullah W, Saleem K, Ahmad E, Anwer F. Rapunzel syndrome: a rare cause of hypoproteinaemia and review of literature. *BMJ Case Rep*. 2016; 2016: bcr2016216600.
17. Nour I, Abd Alatef M, Megahed A, Yahia S, Wahba Y, Shabaan AE. Rapunzel syndrome (gastric trichobezoar), a rare presentation with generalised oedema: case report and review of the literature. *Paediatr Int Child Health*. 2019; 39(1): 76-78.

18. Khanna K, Tandon S, Yadav DK, Khanna V. Rapunzel syndrome: a tail too long to tell! *BMJ Case Rep.* 2018; 2018: bcr-2018-224756.
19. Jensen AR, Trankiem CT, Lebovitch S, Grewal H (2005) Gastric outlet obstruction secondary to a large trichobezoar. *J Pediatr Surg* 40:1364–1365.
20. Coulter R, Anthony MT, Bhuta P, Memon MA (2005) Large gastric trichobezoar in a normal healthy woman: case report and review of pertinent literature. *South Med J* 98:1042–1044.
21. Bustos R, Gheza F, Masrur M. Snapshot in surgery: how do you approach this 12-year-old girl? *Clin Case Rep.* 2018; 6(7): 1389-1390.
22. Nirasawa Y, Mori T, Ito Y, Tanak H, Seki N, Atomi Y (1998) Laparoscopic removal of a large gastric trichobezoar. *J Pediatr Surg* 33:663–665.
23. Wang YG, Seitz U, Li ZL, Soehendra N, Qiao XA (1998) Endoscopic management of huge bezoars. *Endoscopy* 30:371–374
24. Kanetaka K, Azuma T, Ito S, Matsuo S, Yamaguchi S, Shirono K et al (2003) Two-channel method for retrieval of gastric trichobezoar: report of a case. *J Pediatr Surg* 38:1–2.
25. Saeed ZA, Ramirez FC, Hepps KS et al (1993) A method for the endoscopic retrieval of trichobezoars. *Gastrointest Endosc* 39:698–700
26. Meyer-Rochow GY, Grunewald B (2007) Laparoscopic removal of a gastric trichobezoar in a pregnant woman. *Surg Laparosc Endosc Percutan Tech* 17:129–132
27. Alsafwah S, Alzein M (2000) Small bowel obstruction due to trichobezoar: role of upper endoscopy in diagnosis. *Gastrointest Endosc* 52:784–786.
28. De Backer A, Van Nooten V, Vandenplas Y (1999) Huge gastric trichobezoar in a 10-year-old girl: case report with emphasis on endoscopy in diagnosis and therapy. *J Pediatr Gastroenterol Nutr* 28:513–515.
29. Van Gossum A, Delhaye M, Cremer M (1989) Failure of nonsurgical procedures to treat gastric trichobezoar. *Endoscopy* 21:113
30. Soehendra N (1989) Endoscopic removal of a trichobezoar. *Endoscopy* 21:201.
31. Dumonceaux A, Michaud L, Bonnevalle M, Debeugny P, Gottrand F, Turck D (1998) Trichobezoars in children and adolescents. *Arch Pediatr* 5:996–999.
32. Diettrich NA, Gau FC (1985) Postgastrectomy phytobezoar—endoscopic diagnosis and treatment. *Arch Surg* 120:432–435.
33. Gaia E, Gallo M, Caronna S, Angeli A (1998) Endoscopic diagnosis and treatment of gastric bezoars. *Gastrointest Endosc* 48:113–114.
34. Walls LL. Trichobezoar. *Ohio State Med J.* 1976; 72(5): 287-289.
35. Cannalire G, Conti L, Celoni M, et al. Rapunzel syndrome: an infrequent cause of severe iron deficiency anemia and abdominal pain presenting to the pediatric emergency department. *BMC Pediatr.* 2018; 18(1): 125.
36. Hal MV, Kinnane J. et al. Jejunal trichobezoar: A bizarre case of a 3-year-old boy. *Int J Trichol* 2022; 14:28-30