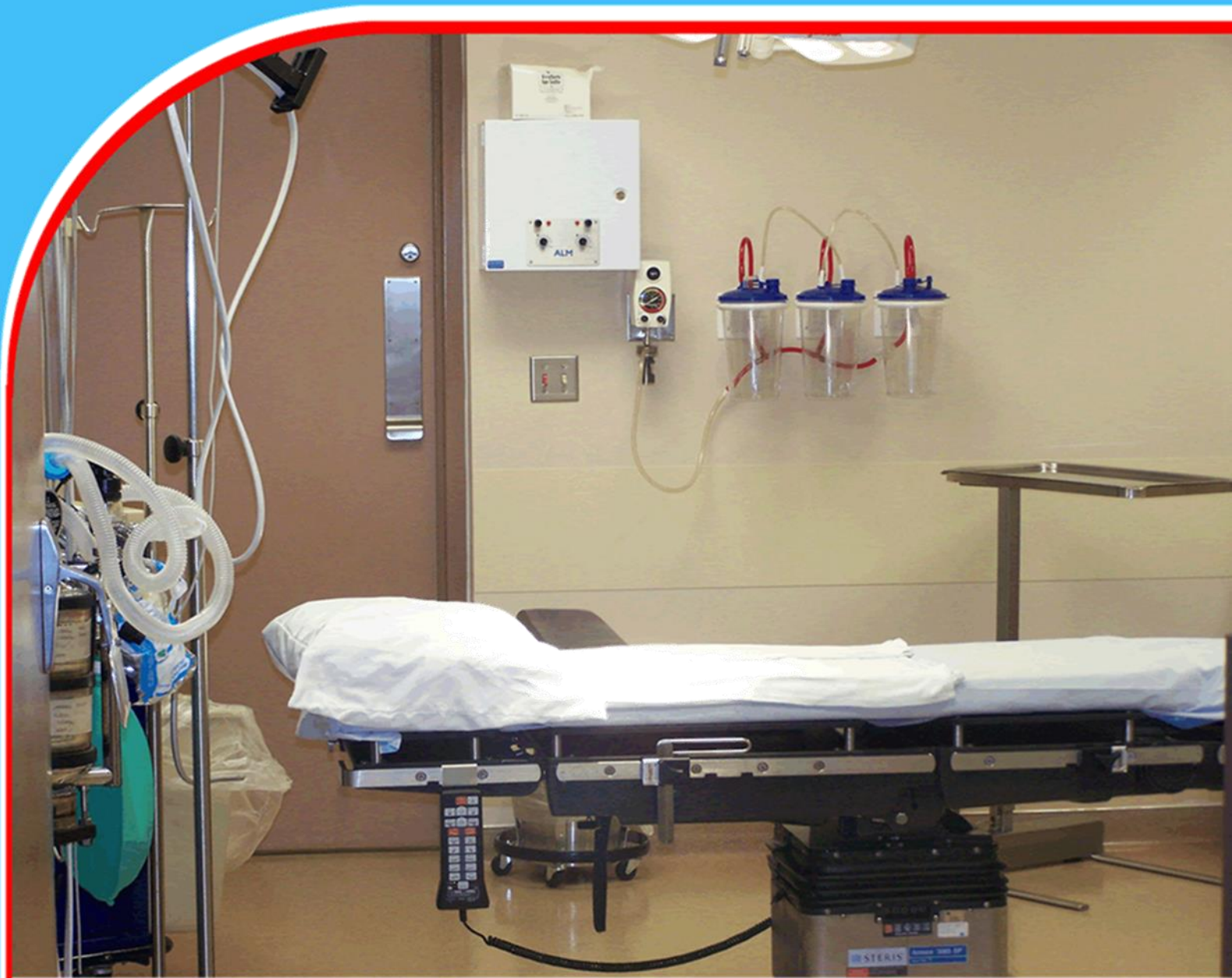

American Journal of Health, Medicine and Nursing Practice (AJHMPN)



The Role of Facial Fillers in Non-Surgical Rhinoplasty: A Systematic Review of Safety and Efficacy

Majid Alhammadi, Ali Mohamed Alsari Almheiri, Khaled Al Zaman




The Role of Facial Fillers in Non-Surgical Rhinoplasty: A Systematic Review of Safety and Efficacy

 Majid Alhammadi^{1*}, Ali Mohamed Alsari Almheiri², Khaled Al Zaman³

¹College of Medicine, University of Sharjah

²College of Medicine, University of Sharjah

³College of Medicine, University of Sharjah



Article history

Submitted 11.12.23; Revised Version Received 18.12.23; Accepted 19.12.23

Abstract

Purpose: Facial fillers, also alluded to as dermal fillers, consist of injectable chemicals as portion of a minimally invasive strategy to incidentally enhance the aesthetic and appearance of facial highlights by correcting volumes. Non-surgical rhinoplasty, also called liquid rhinoplasty, includes the utilize of dermal fillers to improve the shape of the nose. Non-surgical rhinoplasty is picking up popularity over the surgical choice on account of its ease of application, cheaper cost, better safety profile, less adverse effects, and faster recuperation time. Nevertheless, with the complex nasal arterial vasculature and structure, complications have been detailed within the literature. In this review, we examine the distributed applications of facial fillers in non-surgical rhinoplasty and its viability and security profile as compared to the surgical alternative.

Materials and Methods: A comprehensive literature review of articles on facial fillers in non-surgical rhinoplasty was performed. Search results were filtered to incorporate articles and studies that were distributed within the last five years, to increase the relevance of the results to current practices. Search results were then reviewed for significance to the utilize of facial or dermal fillers in non-surgical rhinoplasty only. Studies that detailed the role of face fillers in areas unrelated to rhinoplasty and nose defects were excluded.

Findings: Seven articles met the inclusion criteria and discussed the role, security and viability of facial or dermal fillers in non-surgical rhinoplasty. Of these, three were designed to illustrate particular techniques embraced in non-surgical rhinoplasty as well as the common uses of diverse and common fillers. The remaining three reviewed the safety and viability of

particular filler sorts: one article inspected the use of Hyaluronic corrosive based dermal fillers in non-surgical rhinoplasty, another reviewed the strategy of PMMA-collagen gel in non-surgical rhinoplasty absconds, and finally, a study analyzed the utilize of a hybrid nasal filler which combined agarose gel and hyaluronic corrosive. The remaining article from the literature reviewed a case from a patient who detailed persistent headache and migraine-like indications following non-surgical rhinoplasty.

Conclusions: Facial fillers are compelling and safe options for patients who wish to rectify or enhance their nasal shape or form, without going for surgery. Although the results are not as permanent as with the surgical alternative, non-surgical rhinoplasty offers a better recovery time, and cheaper cost. Given the distinctive properties ascribed to each filler type, and the diverse cases of nasal deformities, the filler choice and area should be chosen on a patient-specific basis. Compared to surgical rhinoplasty, the complications and adverse occasions from the non-surgical injections are as a rule mild and self-limiting. While severe complications are uncommon, deep knowledge of the nasal anatomy and vasculature, as well as extensive training, stay the main ways to minimize their event and increase patient security and satisfaction.

Implications to Theory, Practice and Policy: Severe complications are uncommon, deep knowledge of the nasal anatomy and vasculature, as well as extensive training, remain the main ways to minimize their event and increase patient safety and fulfillment. In any case, more studies are required to clearly establish the safety of dermal fillers, particularly in the long-term.

Keywords: *Facial Fillers, Dermal Fillers, Non-Surgical Rhinoplasty, Safety, Efficacy*

1.0 INTRODUCTION

Facial fillers, also alluded to as dermal fillers, comprise of injectable chemicals as part of a minimally invasive method to temporarily upgrade the aesthetic and appearance of facial highlights by correcting volumes. They are most commonly infused to lips, cheeks, facial creases, wrinkles, and scars. Recently, facial fillers are replacing the need for plastic surgery, this is due to them being a safer, cheaper, and better alternative for patients. One of their downsides is their temporary impacts. A few types of dermal fillers are present on the market, each varies in terms of attributes, aesthetic impacts, durability and degradation, adverse impacts, and complications. The most common sorts incorporate: Calcium Hydroxylapatite (CaHA), Hyaluronic acid (HA), Polyalkylimide, Polylactic acid, and Polymethyl-methacrylate microspheres (PMMA)¹. Past literature has illustrated the safe and successful utilize of facial fillers inside the cosmetic field to check the impacts of aging most prevalently. Despite their moderately uncomplicated administration, and ubiquity among patients and doctors, complications and adverse events are still worth specifying when it comes to their safety⁶.

Non-surgical rhinoplasty, also called liquid rhinoplasty, includes the utilize of dermal fillers to improve the shape of the nose. It can be conducted as an alternative to surgical rhinoplasty, although not completely supported by few literatures, or to overcorrect the impacts following surgery. Selected applications of facial fillers in non-surgical rhinoplasty incorporate but are not limited to concealment of the dorsal hump, change of the tip's definition or projection, nasal augmentation in case of dorsal deficiency, protracting of the nose, and correction of contour irregularities following surgical rhinoplasty⁷.

Filler choice and selection for non-surgical rhinoplasty ought to be based on the nature of the deformity and its anatomical area. Other components that ought to be accounted for when selecting a filler incorporate the longevity of the results, and the moldability and flexibility of the filler after injection^{9,12}. Non-surgical rhinoplasty is picking up popularity over the surgical choice on account of its ease of application, cheaper cost, better security profile, less adverse effects, and speedier recovery time. Nevertheless, with the complex nasal arterial vasculature and structure, complications and unfavorable events have been detailed within the literature^{9,12}. In this review, we examine the distributed role of facial fillers in non-surgical rhinoplasty and their adequacy and security profiles as compared to the surgical alternative.

Problem Statement

Facial fillers, also alluded to as dermal fillers, consist of injectable chemicals as portion of a minimally invasive strategy to incidentally enhance the aesthetic and appearance of facial highlights by correcting volumes. Non-surgical rhinoplasty, also called liquid rhinoplasty, includes the utilize of dermal fillers to improve the shape of the nose. Non-surgical rhinoplasty is picking up popularity over the surgical choice on account of its ease of application, cheaper cost, better safety profile, less adverse effects, and faster recuperation time. Nevertheless, with the complex nasal arterial vasculature and structure, complications have been detailed within the literature. In this review, we examine the distributed applications of facial fillers in non-surgical rhinoplasty and its viability and security profile as compared to the surgical alternative.

2.0 MATERIALS AND METHODS

Identification of Studies

To identify published research that reported the use of facial fillers in non-surgical rhinoplasty, a PUBMED search was conducted with the following search parameters:

(facial fillers [MeSH Terms]) OR face fillers[MeSH Terms]) OR PMMA fillers[MeSH Terms]) OR PMMA collagen[MeSH Terms]) OR collagen fillers[MeSH Terms]) AND non-surgical rhinoplasty[MeSH Terms]) OR nose fillers[MeSH Terms]) OR rhinoplasty, non-surgical) OR nose job) OR non-surgical nose job).

Study Selection

Search results were filtered to incorporate articles and studies that were distributed within the last five years, to extend the relevance of the results to current practices. Search results were then reviewed for significance to the utilize of facial or dermal fillers in non-surgical rhinoplasty only. Studies that detailed the role of face fillers in areas irrelevant to rhinoplasty and nose defects were excluded. Studies that inspected the use of uncommon non-dermal fillers, such as fluid cartilage, were excluded as well. Manuscripts related to plastic, reconstructive surgeries, or any procedures including major invasive strategies performed by plastic specialists on nasal defects were excluded.

Data Analysis

Studies were reviewed for reported outcomes of facial fillers in non-surgical rhinoplasty procedures. The patient satisfaction scores presented in each study analysis were accounted for to conclude the overall efficacy of the study. In terms of safety, studies that discussed the emergence of adverse events and complications were also analyzed.

3.0 FINDINGS

Study Attributes

A total of 4271 articles were identified. Following manual screening of the PUBMED search results, 4264 articles were excluded from the analysis as they were either related to surgical rhinoplasty, or to irrelevant topics. Seven articles met the inclusion criteria and discussed the role, safety and efficacy of facial or dermal fillers in non-surgical rhinoplasty. Of these, three were designed to demonstrate specific techniques adopted in non-surgical rhinoplasty as well as the general uses of different and common fillers. The remaining three reviewed the safety and efficacy of specific filler types: one article examined the use of Hyaluronic acid based dermal fillers in non-surgical rhinoplasty, another reviewed the methodology of PMMA-collagen gel in non-surgical rhinoplasty defects, and lastly, a study analyzed the use of a hybrid nasal filler which combined agarose gel and hyaluronic acid. The remaining article from the literature reviewed a case from a patient who reported persistent headache and migraine-like symptoms following non-surgical rhinoplasty.

Applications and Techniques Used for Dermal Fillers in Non-Surgical Rhinoplasty as Presented in the Cosmetic Literature

Hall and Kontis, in their review of non-surgical rhinoplasty, emphasized on the necessity for an extensive knowledge of the nasal anatomy to avoid potentially catastrophic adverse effects.

Vascular anatomy varies between patients, mainly the shape and size of the dorsal nasal artery, and its connection to other nasal arteries⁹. This significant variation led to the conclusion that the safest location for injection of dermal fillers was in the deep areolar plane on the surface of the periosteum and deep to the nasal arteries, in the midline. It comes without saying that the injector or surgeon should be highly knowledgeable of the anatomy and location of the vessels to avoid undesired effects. It is also worth noting that aspiration should be mandatory prior to injecting⁹.

In another article published by Jung¹⁰, 96 patients underwent non-surgical rhinoplasty with a hyaluronic acid filler. A dual plane technique was adopted where a highly elastic hyaluronic acid filler was first injected into the deep fatty layer of the nose, and then a moderately elastic hyaluronic acid filler was injected into the superficial fatty layer. Lastly, the highly elastic filler was injected into the super cartilaginous layer using a retrograde linear threading technique. This technique reduced filler spread into the glabellar area, and further into the nasal bridge and alae, frequently seen with the single layer technique. The dual layer plane technique resulted in an aesthetically longer nose with reduced widening, and few temporary and self-resolving adverse events that ranged from mild erythema to mild ecchymosis in a couple of cases. The satisfaction score adopted in the study was a scale that ranged from 1 to 5: 1-dissatisfied, 2-minimal satisfaction, 3-moderate satisfaction, 4-high satisfaction, and 5-full satisfaction. Immediately after the operation, the author stated that the mean patient satisfaction score was 4.8 ± 0.8 (standard deviation), and 4.7 ± 0.7 after the follow-up session 3 months after the operation.

The author stated that the use of a cannula instead of a needle led to a safer administration and higher patient satisfaction. Nevertheless, to avoid vessel damage complications associated with the use of a cannula, the surgeon should mark the midline of the nose and proceed, through slow bolus injections, without deviating from it¹⁰.

Furthermore, Singh demonstrated practical recommendations in the execution of injection rhinoplasty for enhanced results: for every location of injection, smaller boluses were preferred over big bolus injections. Gentle molding should be done immediately after the injection. In addition, the author encouraged aspirating before injecting to minimize adverse events such as blindness, and avoid massaging the injected area for at least three to four days¹³.

Baser, Singh, Shubhna, Roy and Chaubay (2021) described non-surgical rhinoplasty as a safe, easy, less invasive, non-permanent, and affordable method that can be performed in the outpatient setting. In the study done on 20 patients, Hyaluronic Acid based fillers were applied and a high patient satisfaction score was achieved. However, the knowledge and training of the surgeon in the nasal anatomy and vasculature was once again stated to play an essential role in the efficacy of the procedure. As a general rule, the authors recommended avoiding the deep placement of the filler as it masked the effect of the correction; on the other hand, if placed superficially, it resulted in a nodular appearance. This led to the conclusion that an injection into the subperiosteal plane was preferred².

Filler Choice

Filler choice was discussed in multiple publications. Hyaluronic acid-based fillers were the most commonly used types in the literature. Hyaluronic acid is a naturally-occurring polysaccharide in the human body, with favorable rheological properties. It has a high G-prime profile which can be explained as its recoil effect, or its ability to regain its original shape after deformation, as well as

a high cohesivity (internal adhesion forces), which makes Hyaluronic acid a great filler choice for the nose. In addition, it is easily moldable. The duration of effects of Hyaluronic acid products range from six to eighteen years depending on the formulation and location of the injection^{5,9}.

Buhsem and Kirazoglu explored the use of a hybrid nasal filler which combined Hyaluronic acid and Agarose gel on 32 patients. Agarose has a hydrophobic nature that decreases the swelling effect and allows for minimal migration. These properties were used as an advantage when injected in the locations where augmentation by swelling was undesired, such as the nasal root. Hyaluronic acid was injected in the sites where elevation was desired, such as the nasal tip and the radix. Both filler types were injected slowly in small boluses. The patients did require around two to three revision sessions. At the end of the procedures, self-limiting erythema and swelling at the injection sites were reported for all the participants. Overall, the patients were satisfied with the aesthetic results of the hybrid nasal filler approach⁵.

Rivkin discussed the role of PMMA-collagen gel in non-surgical rhinoplasty. PMMA-collagen gel is considered one of the longer lasting or semi-permanent fillers due to the fact that it is not metabolized or eliminated from the body¹². Moreover, PMMA-collagen gel injections have a permanent effect on the subcutaneous tissues of the nose, as opposed to the Hyaluronic acid-based injections. This alteration in the nasal planes makes future nasal surgeries difficult to achieve, hence patients should be aware of the consequences of this filler type beforehand. It is a biostimulatory filler meaning that the PMMA microspheres generate a fibroblastic response. This, along with the collagen deposition, results in an enhancement of the contour of the nose¹². PMMA microspheres are typically suspended in bovine collagen, hence intradermal testing for allergies in patients is essential prior to the procedure^{9,12}. According to the lead author, PMMA-collagen gel fillers do require revision sessions, usually spaced four to six months apart, and should be reserved to highly skilled and experienced professionals due to the irreversibility of their effects, unlike Hyaluronic acid-based fillers¹².

Lastly, CaHA fillers are formulated as spheres suspended in a carboxymethylcellulose gel carrier. In spite of its metabolism by the body, it is still considered a nonreversible or semi-permanent filler. Its main mechanism of action is the induction of fibroblasts as well as the increase in the production of collagen, a process known as collagenesis for at least a year following the initial injection. CaHA fillers have higher viscosity and G-primer properties than HA fillers which adds to their advantages over the latter⁹.

Patient Evaluations and Contraindications

As expressed within the literature, a complete medical history ought to be obtained from patients prior to the procedure. Verification of the patient's allergy status to any component involved within the process, from the anesthetic agent to the filler, remains crucial⁹. Facial fillers are for the most part contraindicated within the following cases: pregnancy, breastfeeding, immunocompromised patients, and patients with autoimmune diseases². For post-surgical rhinoplasty patients, significant skin-tightness of the nasal soft tissue can be observed in several cases and might compromise the proper situation of the filler and further lead to vascular occlusion. Subsequently, non-surgical rhinoplasty is best avoided in these instances⁹.

Safety and Complications of Dermal Fillers in Non-Surgical Rhinoplasty as Presented in the Cosmetic Literature

As a general rule in the literature, mild adverse events after non-surgical rhinoplasty include mild bruising or ecchymosis, edema, and erythema or redness^{2,9} which are usually self-resolving within a few days and heal without sequelae. Further mild to moderate complications involve hyperpigmentation, formation of nodules, and Tyndall effect manifested as blue discoloration of the skin and usually observed around the eyes after dermal fillers injections (most commonly Hyaluronic acid fillers) due to the skin's thin layer in that area¹¹. While extremely rare, major complications should be taken into consideration; they include vascular occlusions, infections, skin ischemia and necrosis, blindness and vision loss, and stroke. DeVictor et. Al⁸ reported in their systematic review of 37 publications that the complication rate following non-surgical rhinoplasty in 8604 patients was 2.52%. The most common adverse event was bruising which occurred in 1.58% of the cases. From the major complications, transient vessel occlusion accounted for the highest rate (0.35%), followed by vision loss (0.09%), and lastly skin necrosis (0.08%) (Figure 1).

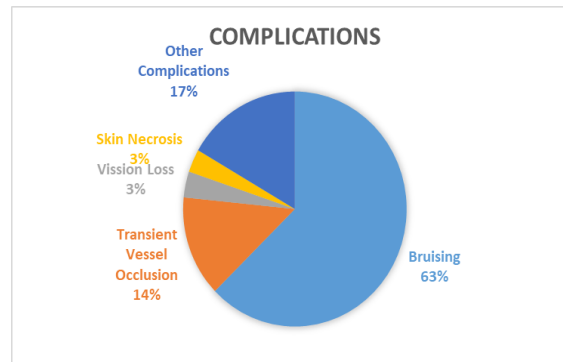


Figure 1: Complications of Dermal Fillers in Non-Surgical Rhinoplasty

The cause of filler-associated blindness is attributed to the retrograde flow of the filler from the dorsal nasal artery and its anastomoses with the external carotid, to the ophthalmic artery system. Belezny et. Al³ concluded in their review of the literature that the dermal filler site that led to the most vision changes was the nasal region (56.3%); Furthermore, in the instances of vision changes, Hyaluronic acid was the most commonly used type of fillers (81.3%), followed by CaHA fillers (10.4%).

Subsequent to their study on hybrid nasal fillers, Buhsem and Kirazoglu⁵ observed that major adverse events and complications following agarose gel injections have not yet been reported in the literature. However, due to the low migration nature of the gel, big bolus injections might lead to lumps, which further highlights the importance of the application technique on the safety and efficacy of the procedure.

In his article on the use of PMMA-collagen gel in non-surgical rhinoplasty, Rivkin discussed the safety of PMMA gel as compared to the Hyaluronic acid counterpart. The author noted a rare complication associated with this type of filler: erythema of the nasal tip that lasted for more than two weeks. The effects were resolved with vascular laser treatment. Yet again, the author emphasized on the significance of a diligent and slow injection on the reduction of the risk of adverse events¹².

Current practices encourage the use of hyaluronidase as a first-line treatment for the management of complications of Hyaluronic acid fillers. It is an enzyme that breaks down hyaluronic acid predominantly in the connective tissue, and reverses the effects of the injections in cases of severe complications such as micro-embolism, vascular occlusion and vision loss^{5,9,12}.

Hyaluronidase can be an effective treatment for the reversal of the effects following PMMA fillers¹² and agarose gel fillers⁵, however, no dissolving agent is yet available for CaHA based to the literature². In their systematic review, Benjamin et. Al⁴ discussed the case of a patient who presented with persistent headache and migraine-like symptoms after non-surgical rhinoplasty with Hyaluronic acid filler injections.

Case Presentation

The patient was a 28-year-old woman, with a healthy medical record and no personal history of headaches or migraines. The patient was interested in a non-surgical rhinoplasty to enhance the appearance of her nasal dorsal hump. Consequently, after agreeing to the procedure, Hyaluronic acid was injected into the radix, dorsum and tip of her nose. The patient reported a bilateral headache that originated just above her brows and radiated to the back of her head. The symptoms began one hour after injections and persisted over the following four days, until the patient returned to the clinic for a re-evaluation, and hyaluronidase was injected to dissolve the fillers.

Despite the patient's attempts to alleviate the “migraine-like” symptoms by taking over-the-counter medications and pain killers, the symptoms were only fully resolved after the dissolution of the fillers. In non-surgical rhinoplasty, the areas of injection have the potential to compress the supraorbital, supratrochlear, and infratrochlear nerves, which are originally the nerves associated with migraine-like symptoms upon entrapment. The literature provides valid anatomical and pathological reasoning for the patient's onset and resolution of the symptoms. Several other articles have also demonstrated that the entrapment of the supratrochlear and infratrochlear nerves leads to migraine-like symptoms, however Benjamin et. al⁴ could not prove whether the filler injections caused the persistent headache in the patient. Nevertheless, their literature review did show that similar complications can occur on rare instances. They concluded that more published literature on the long-term effects of injections on headache symptoms are needed.

Discussion

From our review of the literature, patients and doctors are selecting facial fillers and non-surgical rhinoplasty to easily obtain desirable aesthetic results. What is clear, is that filler infusions are generally secure and effective, and, if applied properly, can lead to few adverse occasions and complications. A common topic expressed in each literature was the importance of the extensive knowledge of the specialist on the anatomy of the nose and its vasculature, along with the properties of the fillers, the infusion strategy, and the proper treatment following the injection if required, on the overall results of the method, safety of the patients, and thus their satisfaction.

Most of the reviewed literature concluded that their involvement with Hyaluronic acid-based fillers yielded high aesthetic satisfaction review with no major adverse occasions. With the accessibility of Hyaluronidase, Hyaluronic acid fillers were favored over other operators for injection rhinoplasty. However, more information is required on a larger scale to validate the results².

Our review highlights studies that tested with different non-surgical rhinoplasty methods, such as the dual plane technique, that demonstrated to be safe and compelling with increased patient satisfaction scores. In spite of that, the procedure was only tried with Hyaluronic acid-based fillers and was highly dependent on the anatomical base of the nose, which demonstrated to differ among patients¹⁰. PMMA-collagen gel fillers, although not as commonly utilized as Hyaluronic acid fillers, appeared effective and more durable results.

Unfortunately, there's little data within the literature on the long-term safety of this sort of fillers¹². Additionally, a combination of fillers demonstrated to be effective aesthetically. The location of each filler agent was carefully chosen based on the property of the filler. In any case, more randomized control trials are needed to evaluate the safety of hybrid nasal fillers⁵.

In conclusion, entrapment neuropathy was noted within the literature to be a rare, yet significant complication of facial fillers in non-surgical rhinoplasty⁴. All things considered, the possibility of placebo effect cannot be disregarded, despite the anatomical and pathological explanations given for the component of migraine-like side effects caused by non-surgical rhinoplasty injections. In this manner, as discussed above, the need of published information regarding long-term follow-up after non-surgical rhinoplasty highlights the need to closely follow-up patients after the procedure⁴.

4.0 CONCLUSION AND RECOMMENDATIONS

Conclusion

Facial fillers are effective and secure options for patients who wish to correct or improve their nasal shape or form, without going for surgery. Although the results are not as lasting as with the surgical alternative, non-surgical rhinoplasty offers a better recovery time, and cheaper cost. Facial fillers are compelling and safe options for patients who wish to rectify or enhance their nasal shape or form, without going for surgery. Although the results are not as permanent as with the surgical alternative, non-surgical rhinoplasty offers a better recovery time, and cheaper cost. Given the distinctive properties ascribed to each filler type, and the diverse cases of nasal deformities, the filler choice and area should be chosen on a patient-specific basis. Compared to surgical rhinoplasty, the complications and adverse occasions from the non-surgical injections are as a rule mild and self-limiting. While severe complications are uncommon, deep knowledge of the nasal anatomy and vasculature, as well as extensive training, stay the main ways to minimize their event and increase patient security and satisfaction.

Recommendations

Given the distinctive properties credited to each filler type, and the diverse cases of nasal deformations, the filler choice and location ought to be chosen on a patient-specific basis. Compared to surgical rhinoplasty, the complications and adverse occasions from the non-surgical infusions are usually gentle and self-limiting. Whereas severe complications are uncommon, deep knowledge of the nasal anatomy and vasculature, as well as extensive training, remain the main ways to minimize their event and increase patient safety and fulfillment. In any case, more studies are required to clearly establish the safety of dermal fillers, particularly in the long-term.

REFERENCES

1. American Society of Plastic Surgeons. (2023). American Society of Plastic Surgeons. <https://www.plasticsurgery.org/cosmetic-procedures/dermal-fillers/types>
2. Baser, B., Singh, P., Shubha, P., Roy, P. K., & Chaubey, P. (2021). Non-surgical Rhinoplasty and Use of Hyaluronic Acid Based Dermal Filler-User Experience in Few Subjects. *Indian journal of otolaryngology and head and neck surgery : official publication of the Association of Otolaryngologists of India*, 73(1), 52–58. <https://doi.org/10.1007/s12070-020-02100-8>
3. Beleznav, K., Carruthers, J. D. A., Humphrey, S., Carruthers, A., & Jones, D. (2019). Update on Avoiding and Treating Blindness From Fillers: A Recent Review of the World Literature. *Aesthetic surgery journal*, 39(6), 662–674. <https://doi.org/10.1093/asj/sjz053>
4. Benjamin, M., McGregor, A., Yousif, S., Shaikh, D., & Reish, R. G. (2020). Entrapment Neuropathy Causing Persistent Headache Symptoms after Nonsurgical Rhinoplasty. *Plastic and reconstructive surgery. Global open*, 8(12), e3209. <https://doi.org/10.1097/GOX.0000000000003209>
5. Buhsem, O., & Kirazoglu, A. (2022). Hybrid Nasal Filler: Combining Agarose Gel and Hyaluronic Acid for Nonsurgical Rhinoplasty. *Plastic and reconstructive surgery. Global open*, 10(4), e4236. <https://doi.org/10.1097/GOX.0000000000004236>
6. Clark, N. W., Pan, D. R., & Barrett, D. M. (2023). Facial fillers: Relevant anatomy, injection techniques, and complications. *World Journal of Otorhinolaryngology - Head and Neck Surgery*, 9(3), 227–235. <https://doi.org/10.1002/wjo2.126>
7. Clinic, C. (2022). Nonsurgical Rhinoplasty (Nose Job): What It Is, Uses & Procedure. Cleveland Clinic. <https://my.clevelandclinic.org/health/treatments/22880-nonsurgical-rhinoplasty-nose-job>
8. DeVictor, S., Ong, A. A., & Sherris, D. A. (2021). Complications Secondary to Nonsurgical Rhinoplasty: A Systematic Review and Meta-analysis. *Otolaryngology--head and neck surgery : official journal of American Academy of Otolaryngology-Head and Neck Surgery*, 165(5), 611–616. <https://doi.org/10.1177/0194599820987827>
9. Hall, S. S., & Kontis, T. C. (2023). Nonsurgical rhinoplasty. *World journal of otorhinolaryngology - head and neck surgery*, 9(3), 212–219. <https://doi.org/10.1002/wjo2.104>
10. Jung G. S. (2019). Filler rhinoplasty based on anatomy: The dual plane technique. *JPRAS open*, 20, 94–100. <https://doi.org/10.1016/j.jptra.2019.04.002>
11. King, M. (2016). Management of Tyndall Effect. *The Journal of Clinical and Aesthetic Dermatology*, 9(11), E6–E8. <https://www.ncbi.nlm.nih.gov/pmc/articles/PMC5300720/>
12. Rivkin A. (2022). PMMA-collagen Gel in Nonsurgical Rhinoplasty Defects: A Methodological Overview and 15-year Experience. *Plastic and reconstructive surgery. Global open*, 10(8), e4477. <https://doi.org/10.1097/GOX.0000000000004477>
13. Singh, S. (2019). Practical Tips and Techniques for Injection Rhinoplasty. *PubMed*, 12(1), 60–62. https://doi.org/10.4103/jcas.jcas_137_18

License

Copyright (c) 2023 Ali Mohamed Alsari Almheiri, Majid Alhammadi, Khaled Al Zaman



This work is licensed under a [Creative Commons Attribution 4.0 International License](https://creativecommons.org/licenses/by/4.0/).

Authors retain copyright and grant the journal right of first publication with the work simultaneously licensed under a [Creative Commons Attribution \(CC-BY\) 4.0 License](https://creativecommons.org/licenses/by/4.0/) that allows others to share the work with an acknowledgment of the work's authorship and initial publication in this journal.