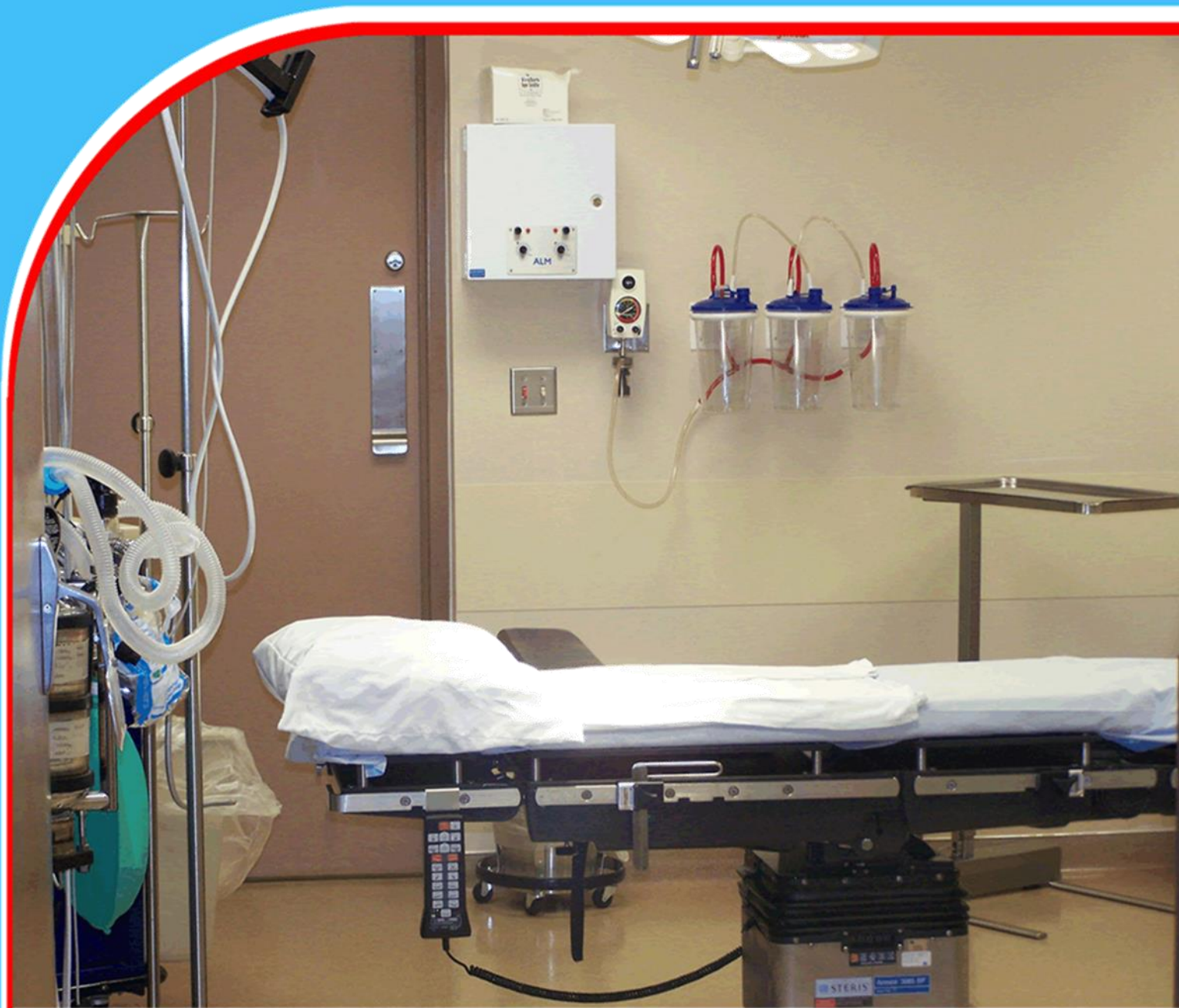

American Journal of Health, Medicine and Nursing Practice (AJHMN)




A Case of Orbital Rhabdomyosarcoma with Intracranial Extension in an Adult: Diagnostic and Management Challenges

*Oduware, Gloria Ugboaku , Edema, Temituoyo Folusho, Ikhile,
Emmanuel Aimebelomo, Eghobamien Mine Oghomwenoyemwen
& Edema, Omolabake Tolutope*



A Case of Orbital Rhabdomyosarcoma with Intracranial Extension in an Adult: Diagnostic and Management Challenges

 **Oduware Gloria Ugboaku (MBBS)^{1*}, Edema, Temituyo Folusho (MD)², Ikhile Emmanuel Aimebelomo³, Eghobamien Mine Oghomwenoyemwen (MBBS)⁴ & Edema Omolabake Tolutope⁵**

¹Senior Registrar, Department of Ophthalmology, University of Benin Teaching Hospital, Benin City, Nigeria

²Medical Officer, JIL Specialist Eye Clinic, Benin-City, Nigeria

³Consultant Radiation and Clinical Oncologist, Department of Radiation and Clinical Oncology University of Benin Teaching Hospital, Benin City, Nigeria

⁴Senior Registrar, Department of Radiology, University of Benin Teaching Hospital, Benin City, Nigeria

⁵Professor/ Consultant Ophthalmologist, Department of Ophthalmology, University of Benin Teaching Hospital, Benin City, Nigeria



Article history

Submitted 03.09.2023 Revised Version Received 26.09.2023 Accepted 08.10.2023

Abstract

Purpose: To report a rare case of orbital rhabdomyosarcoma with intracranial extension in an adult and the challenges in managing this case.

Methodology: Research design was through a case report, while data was collected through observation, analysis of medical records and individual interviews. Interpretation of data was through the qualitative method of data analysis.

Findings: A 34-year-old female meat seller was referred to our center with a rapidly progressive protrusion of the right eye of one month duration. She had a previous history of a penetrating injury to the right globe with bone fragment retention. She had had evisceration. Two weeks post-surgery, she noticed pain and a progressively worsening swelling around the right orbit. In our center, an initial diagnosis of orbital cellulitis post-evisceration was entertained. Orbito-cranial CT scan and MRI done showed a large homogenous irregular soft tissue mass occupying the right orbital cavity with extension to the right lateral rectus, lacrimal gland, cavernous sinus, optic nerve and brain parenchyma; findings were suggestive of orbital rhabdomyosarcoma with intracranial extension. The patient was discharged against medical advice. She re-presented 7 weeks later with a much larger mass which had multiple friable

bleeding sites. With much assurance by the oncologists, she had several blood transfusions and 6 courses of chemotherapy. Tumour regression was very impressive. Incisional biopsy and histology confirmed rhabdomyosarcoma with chemotherapeutic changes. The patient was stable and so referred to another tertiary center for External Beam Radiation Therapy (EBRT), but this was delayed due to financial constraints. Two months from her referral for EBRT, colleagues reported she died of intractable seizures

Recommendations: This study is based on suggestions that therapeutic success for rhabdomyosarcoma is better in children with survival rates reaching 75% unlike in adults where prognosis is poor.¹ In this report, remission was observed soon after commencement of treatment. Therefore, it is recommended that early diagnosis be done to improve outcomes. Secondly, combination drugs should be used in all rhabdomyosarcoma cases. Lastly, government policies geared towards universal health coverage should be made and implemented.

Keywords: *Rhabdomyosarcoma, Radiologic Imaging, External Beam Radiation Therapy, Late Presentation, Chemotherapy Remission.*

1.0 INTRODUCTION

Rhabdomyosarcoma (RMS) is a rare, highly malignant tumor that arises from the primitive mesenchymal cells which have the propensity to differentiate into striated muscles. It is the most common soft tissue sarcoma in children and adolescents, accounting for approximately 5% of all pediatric cancers.² RMS presents commonly as a malignant neoplasm of the head and neck in children, with about 10-15% of the head and neck cases occurring in the orbit.³ The most usual age range of diagnosis is <15 years and an incidence of about 4-7 cases per million.⁴⁻⁵ In Nigeria, some authors reported 35 cases over a 10-year period³, 91 cases over a 20-year period⁴ and 52 cases over 15 years⁶. The most common histological type in these studies was the alveolar type and they also reported slight preponderance in males over females⁴⁻⁶. Among the population age group between 0–19 years, an estimated 350 new cases of RMS are diagnosed each year in the United States⁷.

RMS is infrequent in adults; soft tissue sarcomas represent <1% of all adult solid tumor malignancies, and RMS accounts for only 3% of all soft tissue sarcomas in adults.⁸ Malu et al⁹ described a case of an 11 year old boy in Markurdi, Nigeria whose management was challenging to the attending medical team because of gross financial difficulties. Fasina in Ibadan, reported 22 patients with orbital RMS seen over a 20 years period with age range of 2 months to 50 years.¹⁰ All his patients presented late with visual loss, orbital swelling and proptosis. Embryonal RMS was reported in 72.7% of these patients, but treatment outcome was poor as only two (9.1%) patients remained tumor-free 12 and 36 months after diagnosis while fifteen (68.2%) patients were lost to follow-up. Again, financial constraint and perceived poor response to treatment were highlighted as the main reasons why patients did not complete or were inconsistent with their treatment¹⁰. We wish to present a case of a 34 year old woman that posed much difficulty because she withheld pertinent history. This resulted in an evisceration in a secondary health center followed by the manifestation of an aggressive growth on account of which she was sent to us in a tertiary center.

Theory of the Study

This study is premised on the finding that rhabdomyosarcoma in adults is associated with an unfavorable prognosis.^{1,12} This claim was substantiated by the aggressive nature of the disease leading to the unfortunate demise of the patient, as documented in this case report.

2.0 METHODOLOGY

Research Design: This study is a case report

Method of Data Collection: Collection was done through observation, analysis of medical records and individual interviews.

Analysis: Interpretation of data was through the qualitative method of data analysis

Case Presentation

A 34 year old female meat seller from Benin City, Nigeria was referred to University of Benin Teaching Hospital (UBTH) eye clinic with a history of ‘protrusion of her right eye’ of one month duration. Protrusion of the right eye was gradual in onset, progressive and associated with pain, redness and milky discharge. Three weeks prior to this, she had a penetrating injury to the right eye while butchering meat in the market. This resulted in loss of vision, right globe rupture and bone fragment retention for which an eye removal surgery was done at a peripheral hospital.

Her review of systems was essentially normal. Although topical ocular medications were prescribed for her, she also instilled her own urine and some leaf extracts into her right eye post operatively. Two weeks post-surgery, she noticed pain and a progressively increasing swelling within the right orbit. General examination revealed a young lady in mild painful distress, afebrile, not pale, anicteric, not

dehydrated, acyanosed and no palpable lymphadenopathy. Patient was well oriented in time, place and person; all systems were normal. However, ocular examination showed a visual acuity of no light perception in the right eye (RE) and 6/6 in the left eye (LE). The right adnexa showed marked periorbital edema, the globe appeared to be eviscerated with a moderately large, firm, smooth, hyperemic, tender mass/protrusion of conjunctiva/orbital tissue. The left eye was intact and normal with a pink optic disc (CDR- 0.3).

Initial investigations showed normal hematological and biochemical results. An initial diagnosis of orbital cellulitis post-evisceration was entertained and the patient was admitted and placed on IV antibiotics: Ceftriaxone, Metronidazole and Gentamycin for three days. She could not pay for imaging studies immediately, but when we noticed there was no reduction in size of the mass, more pressure was put on the family for a cranial CT scan. Co-incidentally, the radiologist recognized our patient as she had done a CT scan on her for the same presentation a few months earlier. At that time, she had diagnosed her scan as a case of rhabdomyosarcoma. CT requested by our team was consistent as it showed a large homogenous irregular soft mass occupying the right orbital cavity, infiltrating the right lateral rectus and lacrimal gland with displacement and enlargement of the right optic nerve. Brain MRI also showed an orbital tumor extending to the right lateral rectus, right optic nerve, medial rectus, optic canal and right cavernous sinus. Both imaging techniques were suggestive of a right-sided orbital rhabdomyosarcoma with intracranial extension.

The patient was informed of the radiological findings and immediately referred to the oncologists, but despite counseling, she preferred to be discharged against medical advice. However, she re-presented in the eye clinic about 7 weeks later in much distress: she was ill looking, with a much larger, irregular, bleeding mass covered in many layers of dressing. Exposure of the mass for ophthalmological inspection caused quite a stir as there were multiple friable bleeding sites. She was immediately referred to the Oncology department where she was admitted; she had several pints of blood transfused and six courses of chemotherapy (VAC-P: Vincristine, Adriamycin, Cyclophosphamide, and Cisplatin Regimen). Tumor regression was very impressive, she looked well and was happy with her progress (see figures 4,5). At the request of the oncologists, post chemotherapy, an incisional biopsy (she could not have this earlier) was done by ophthalmology as a histological diagnosis was needed for post-chemotherapy assessment. Histology described a malignant, neoplastic lesion with hyperchromatic cells, pleomorphic nuclei, scanty to abundant eosinophilic cytoplasm, there were a few strap cells and rhabdomyoblast-like cells. She was discharged to the outpatient clinic having spent about two months in the hospital.

However, a month after being discharged, she developed seizures and had to be re-admitted. She was managed with IV mannitol, IV dexamethasone and tabs phenytoin. Thereafter, she was referred to another tertiary center in another city for External Beam Radiotherapy (EBRT), but this move was delayed due to financial constraints. Two months later, she was able to pool together the needed resources but she had to be on a queue for EBRT in that center. Her family reported that she died of intractable seizures while still waiting for the opportunity to have EBRT.

Discussion

Backhouse et al¹¹ reported a case of orbital embryonal rhabdomyosarcoma in which diagnosis was delayed by several weeks due to a concurrent history of repeated trauma. Currently, 5 year overall survival (OS) of children exceeds 70% for non-metastatic RMS^{3,9-10}. RMS is rare in adults; very few adult cases are reported in literature and in contrast, the outcome of adult patients remains poor¹². Various genetic predispositions have been identified, including variants of the RB1 gene responsible for retinoblastoma¹⁰. Histological types include embryonal, alveolar, botyroid and pleomorphic⁴⁻⁶. Clinical features may mimic inflammatory conditions such as orbital cellulitis¹³. A case report in a 25

year old man was masked by ethmoidal sinusitis¹². It presented as an orbital apex syndrome in a 12 year old boy¹⁴

Rhabdomyosarcoma could cause an acute, rapidly progressive proptosis, globe displacement, blepharoptosis, conjunctival and eyelid swelling, palpable mass, diplopia, pain (rare)^{3,12}. The tumor location- most commonly superonasal or superiorly (25%)^{3,9,12}. It may arise in the conjunctiva or uvea; intracranial extension of the tumor is usually by bony erosion through perforation on the medial side of the orbit or in the inferior orbital wall.¹³ Metastatic spread is uncommon but can spread to the lung, bone and bone marrow. Multidisciplinary management could include specialists from neurosurgery, neuro-ophthalmology, head and neck, neuropathology, oculoplastic, neuroradiology, oncology, pediatrician, and neurologist.

The challenges encountered with the index case included:

- i. Incorrect initial diagnosis: The patient was referred from a secondary center by an ophthalmologist [referring surgeon] after having an evisceration for possible retention of bone fragment in the right globe. The surgeon presumed that the globe had ruptured following penetrating injury while butchering meat. The referring physician carried out the ocular surgery (evisceration) but did not find any retained bone fragment. In actual fact her history of globe injury was imagined and misleading. Post operatively, her presentation, including use of traditional herbal eye medication and urine made the referring surgeon manage her as post -surgical orbital cellulitis. She presented a similar story and so she was admitted and given more potent intravenous antibiotics. Literature shows that rhabdomyosarcoma could present as an acute, rapid inflammation with features suggestive of infections.^{3,9} The real story was revealed when she confirmed that she had a CT done earlier (as mentioned by the radiologists, but she hid this information from the referring surgeon. She lost treatment time)
- ii. Rhabdomyosarcoma is common in children (most common soft tissue sarcoma, 87% present before 15 years), but rare in adults (1% of soft tissue sarcomas)⁴. Orbital rhabdomyosarcoma is reported in less than 15% of all RMS cases. Fewer cases have been reported in Nigeria - 5 per year⁹, while USA reports 350/year⁷
- iii. Patient was discharged against medical advice. Time was of essence in managing this index case. Even though the tumor was large, it was still covered with a smooth conjunctival surface at her first presentation in UBTH. Just seven more weeks of negligence due to ignorance produced a very dramatic situation: a huge mass, irregular friable lesion eroding the blood vessels and the ophthalmic nurses battling to put a dressing good enough for haemostasis.
- iv. Financial constraints prevented a smooth and immediate transition to the EBR center outside Benin where she resides.
- v. EBRT machine in UBTH had been broken down for a while. The other hospital with this equipment often has a queue as there are not enough of such centers for the millions who need such oncology treatment services in Nigeria.

3.0 CONCLUSION AND RECOMMENDATIONS

Conclusion

Orbital RMS is a rapidly progressive disease, one of the few life-threatening diseases that presents first to the ophthalmologist. Prompt diagnosis through the knowledge of the clinical, histopathological, and radiographic features as well as the more recent advances in the management of this entity is necessary for survival. Orbital rhabdomyosarcoma is rare, and even scarcer in adults. It is likely to be misdiagnosed as it presents with similar features as other orbital diseases. Intracranial extension

presents a more sinister prognosis. A multidisciplinary approach for the treatment of orbital RMS is essential. Early diagnosis, early management and availability of funds for EBR would have been of immense prognostic help for this patient.

Recommendations

The following recommendations are being offered based on the findings in this case report:

1. To medical practitioners. Early diagnosis can be achieved by having a high index of suspicion for an orbital rhabdomyosarcoma whenever an ocular swelling or protrusion is seen. This will help expedite treatment and as a result, reduce morbidity and mortality. Secondly, combination chemotherapy should be administered as this has been shown to be more effective than single-drug chemotherapy regimens.
2. To non-governmental organizations (NGOs). NGOs can play a crucial role in promoting patient education. This can lead to an increase in early presentation of patients at the health facilities. In addition, the NGOs can collaborate with governmental organizations to support initiatives that enhance cancer treatment.
3. To policy makers. Policy reforms aimed at ensuring access to cancer care for all should be made. Some of the policies include providing universal health coverage, ensuring availability of cancer drugs, equipping hospitals with the latest technology for cancer treatment and providing adequate funding for cancer research.

REFERENCES

1. Wu, T. H., Huang, J. S., Wang, H. M., Wang, C. H., & Yeh, K. Y. Wu, Tsung & Huang, Jen-Seng & Wang, Hung-Ming & Wang, Cheng-Hsu & Yeh, Kun-Yun. (2010). Long-term survivors of adult rhabdomyosarcoma of maxillary sinus following multimodal therapy: Case reports and literature reviews. *Chang Gung Medical Journal*, 33(4), 466–471.
2. Egas-Bejar, D., & Huh, W. W. (2014, June 17). Rhabdomyosarcoma in adolescent and young adult patients: Current perspectives. *Adolescent Health, Medicine and Therapeutics*, 5, 115–125.
3. Jurdy, L., Merks, J. H., Pieters, B. R., Mourits, M. P., Kloos, R. J., Strackee, S. D., & Saeed, P. (2013, July). Orbital rhabdomyosarcomas: A review. *Saudi Journal of Ophthalmology*, 27(3), 167–175.
4. Mandong, B. M., & Ngbea, J. A. (2011, October–December). Childhood rhabdomyosarcoma: A review of 35 cases and literature. *Nigerian Journal of Medicine*, 20(4), 466–469.
5. Brown, B. J., & Oluwasola, A. O. (2006, December). Childhood rhabdomyosarcoma in Ibadan, Nigeria: 1984–2003. *Annals of Tropical Paediatrics*, 26(4), 349–355.
6. Raphael, S., Yusuf, I., & Imam, I. (2015, January–March). Childhood rhabdomyosarcoma in Kano, Nigeria: A retrospective analysis of 52 cases. *Nigerian Journal of Medicine*, 24(1), 32–36.
7. Linet, M. S., Ries, L. A., Smith, M. A., Tarone, R. E., & Devesa, S. S. (1999, June 16). Cancer surveillance series: Recent trends in childhood cancer incidence and mortality in the United States. *Cancer Surveillance Series. Journal of the National Cancer Institute*, 91(12), 1051–1058.
8. Ferrari, A., Dileo, P., Casanova, M., Bertulli, R., Meazza, C., Gandola, L., Navarra, P., Collini, P., Gronchi, A., Olmi, P., Fossati-Bellani, F., & Casali, P. G. (2003, August 1). Rhabdomyosarcoma in adults. A retrospective analysis of 171 patients treated at a single institution. *Cancer*, 98(3), 571–580.
9. Malu, K., Ngbea, J., Mohammand, H., Mohammand, H., Joseph A & Mohammad. (2015) Primary orbital rhabdomyosarcoma in an 11-year-old boy: A management challenge in a resource limited environment. *Journal of Medicine in the Tropics*, 17(1).
10. Fasina, O. (2013, June). Pattern of presentation and outcome of ophthalmic rhabdomyosarcoma in Ibadan. *African Journal of Medicine and Medical Sciences*, 42(2), 165–169.
11. Backhouse, O. C. E., Cove, P., & Bowen, D. I. (1997). Rhabdomyosarcoma masked by orbital trauma. *International Journal of Oral and Maxillofacial Surgery*, 26(5), 374–375, ISSN 0901-5027.
12. Andrade, A. A. M. (2017). Orbital rhabdomyosarcoma in an adult, case report. *Arch. Journal of Surgery*, 3(1), 11–13.
13. Sanz-Marco, E., España, E., Alamar, A., Pérez-Rojas, J., López-Prats, M. J., & Díaz-Llopis, M. (2014, May). Rbdomiosarcoma alveolar orbitario enmascarado por sinusitis etmoidal en un adulto de 25 años [Orbital alveolar rhabdomyosarcoma masked by ethmoid sinusitis in a 25-year-old]. *Archivos de la Sociedad Española de Oftalmología*, 89(5), 182–185. ISSN 2173-5794.
14. Machleder, D. J., Banik, R., Rosenberg, R. B., & Parikh, S. R. (2005, February). An unusual case of rhabdomyosarcoma presenting as orbital apex syndrome. *International Journal of Pediatric Otorhinolaryngology*, 69(2), 249–254..

ILLUSTRATIONS

Figure 1: An Axial Unenhanced Cranial CT scan at the Level of the Orbits. CT Scan Done Months Before Eye Removal and Presentation in University of Benin Teaching Hospital. Report Was Recovered by Coincidence.

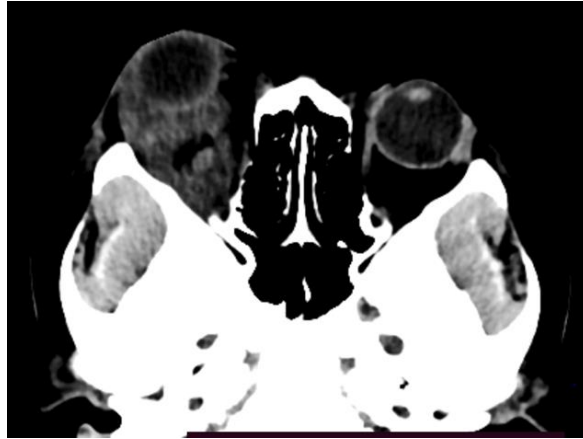


Figure 2: There is an Ill-Defined, Enhancing Mass in the Right Lateral Intra-Conal Space Measuring about 4.0 X 2.6cm in Size (AP X H). The Margins of the Mass Cannot be Separated from the Posterolateral Aspect of the Optic Nerve with Increase in Size and Indistinctness of the Right Lateral Rectus Muscle (Taken before Presentation in UBTH).

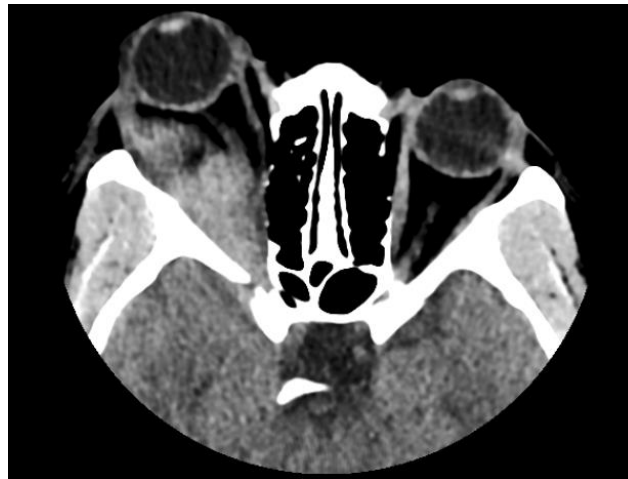


Figure 3: There Was No Gross Evidence of Bony Infiltration

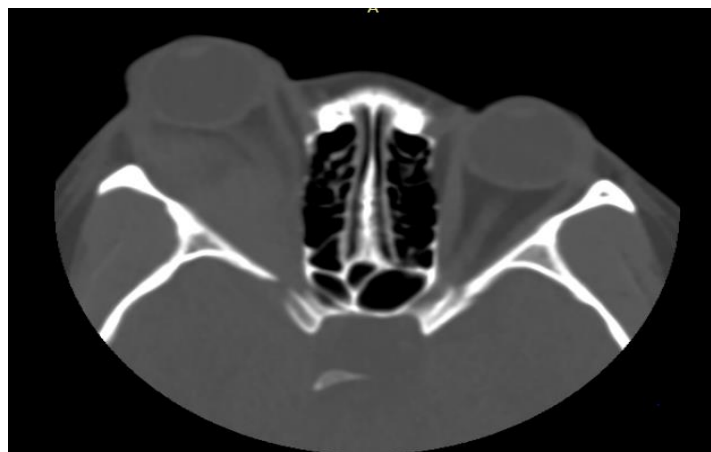

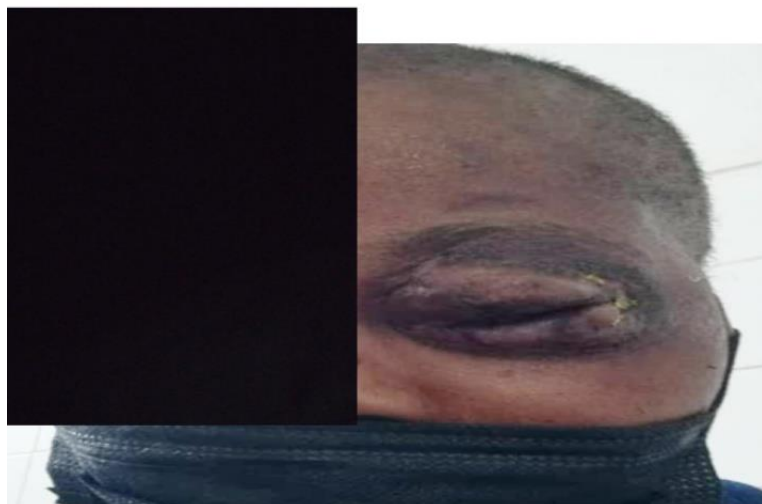
Fig 4: Within First Few Days of Admission in UBTH Oncology Unit

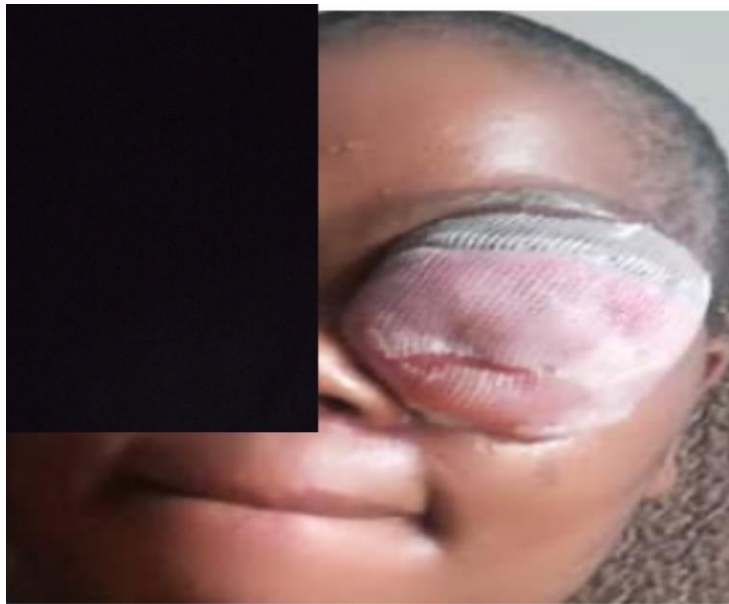

Fig 5: Midway through Chemo-Treatment

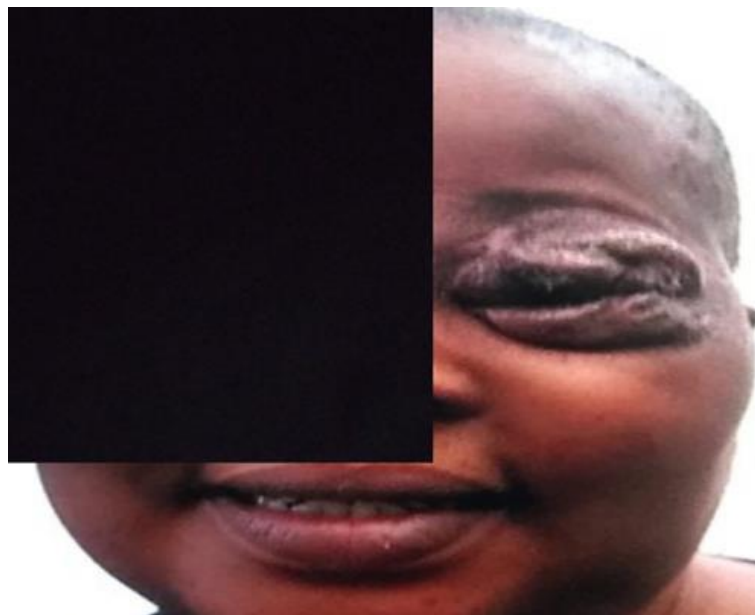

Figure 6: After Chemotherapy



Acknowledgments

We acknowledge the wonderful staff of Oncology Unit [UBTH] who aided the patient when she was so vulnerable.

Disclosure of Conflict of Interest

The authors declare no conflict of interest

Statement of Ethical Approval

Ethical approval was sought and obtained from the hospital's ethical committee.

Statement of Informed Consent

This was gotten from the family of the patient.

License

Copyright (c) 2023 Oduware Gloria Ugboaku (MBBS), Edema, Temituoyo Folusho (MD), Ikhile Emmanuel Aimebelomo, Eghobamien Mine Oghomwenoyemwen (MBBS), Edema Omolabake Tolutope



*This work is licensed under a [Creative Commons Attribution 4.0 International License](https://creativecommons.org/licenses/by/4.0/).
Authors retain copyright and grant the journal right of first publication with the work simultaneously licensed under a [Creative Commons Attribution \(CC-BY\) 4.0 License](https://creativecommons.org/licenses/by/4.0/) that allows others to share the work with an acknowledgment of the work's authorship and initial publication in this journal.*