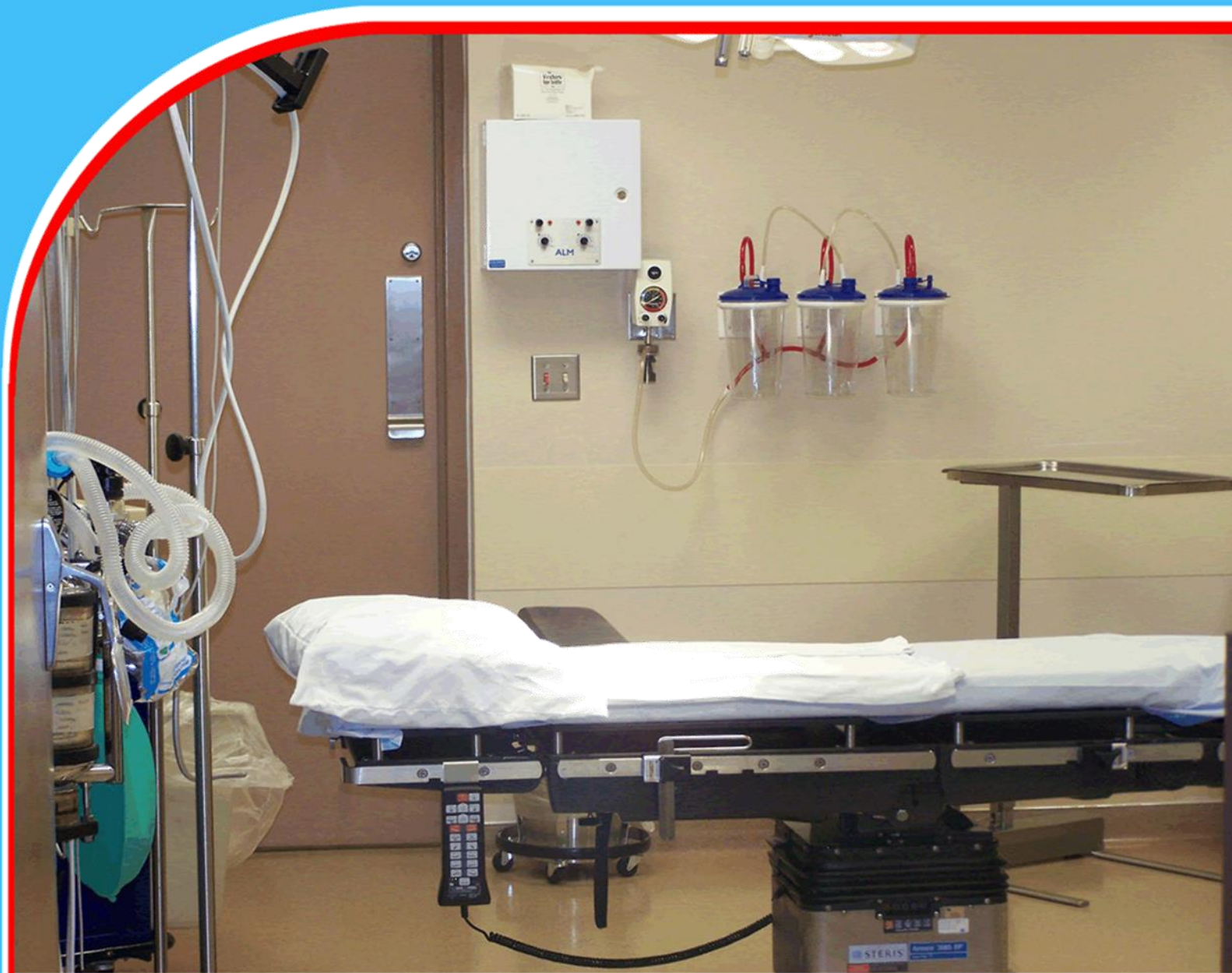

# American Journal of Health, Medicine and Nursing Practice (AJHMN)










## **Takotsubo Cardiomyopathy: Broken Heart Syndrome in A Tertiary Teaching & Referral Hospital in East Africa: Case Report & Literature Review**

*Dr. Adegu William, Dr. Kevin Chesoni, Dr. Donald Madekwe, Dr.  
Aluora Kenneth, Dr. Benjamin Wabwire,  
Prof. Khainga Stanley & Dr. Nang'ole Ferdinand*



## Takotsubo Cardiomyopathy: Broken Heart Syndrome in A Tertiary Teaching & Referral Hospital in East Africa: Case Report & Literature Review

 Dr. Adegu William<sup>1</sup>,  Dr. Kevin Chesoni<sup>1</sup>,  Dr. Donald Madekwe<sup>1</sup>,  Dr. Aluora Kenneth<sup>2</sup>,  Dr. Benjamin Wabwire<sup>2</sup>,  Prof. Khainga Stanley<sup>1</sup> &  Dr. Nang'ole Ferdinand<sup>1</sup>

<sup>1</sup>Department of Plastic, Reconstructive & Aesthetic Surgery, University of Nairobi, Nairobi, Kenya

<sup>2</sup>Kenyatta National Hospital, Kenya



Article history

*Submitted 13.08.2023 Revised Version Received 22.08.2023 Accepted 18.08.2023*

### Abstract

**Purpose:** Takotsubo cardiomyopathy (TC), also known as broken heart syndrome, refers to an abrupt and short-lived cardiac syndrome that encompasses dramatic left ventricular apical akinesia. Besides mirroring acute coronary syndrome. Patients with Takotsubo cardiomyopathy (broken heart syndrome) usually present with symptoms that are similar to acute coronary syndrome. The patient commonly presents with chest pain, dyspnea, palpitation, nausea and vomiting, syncope as well as cardiogenic shock. However, Takotsubo cardiomyopathy usually occurs in association with a preceding physical or emotional stressful event.

**Methodology:** A 25-year-old black female presented to the largest teaching & referral hospital in Kenya with chest pain, dyspnea, palpitations, nausea and vomiting. The patient was received in the emergency room where she was stabilized, a battery of investigations ordered and a diagnosis of TC was made after reviewing

the results. She was managed as an inpatient on appropriate medication

**Findings:** Patient generally responded positively to the treatment and tolerated well the surgical procedures. Follow up echocardiograms performed weekly revealed progressive reduction in size of the thrombus, which had completely resolved at 4 weeks. There was no more thrombi formation after thromboembolectomy of the left femoral artery.

**Recommendations:** TC is a rescindable type of cardiomyopathy that is associated with good prognosis and an exceptional morphological characteristic of the left ventricle, that is defined by apical inflating appearance that has been recognized for nearly a quarter a century. We also recommend that patients with identified LV thrombus ought to be anticoagulated till LV function normalizes in addition to the thrombus no longer being present on echocardiogram.

**Keywords:** *Takotsubo Cardiomyopathy, Akinesia, Broken Heart Syndrome, Thrombi*

## 1.0 INTRODUCTION

Takotsubo cardiomyopathy (TC), also known as broken heart syndrome, refers to an abrupt and short-lived cardiac syndrome that encompasses dramatic left ventricular apical akinesia, besides mirroring acute coronary syndrome (1). TC was initially reported in 1990 in Japan. Broken heart syndrome is usually caused by an enormous stressful occurrence, which could either be physical, emotional, or both (2,3). In the current presentation, it was due to both a physical event (above knee amputation of the right limb) as well as an emotional occurrence (tumultuous marriage that had recently turned abusive). Other common risk factors include death of a loved one, sudden illness, severe accidents etc.

Patients with Takotsubo cardiomyopathy (broken heart syndrome) usually present with symptoms that are similar to acute coronary syndrome (4,5). The patient commonly presents with chest pain, dyspnea, palpitation, nausea and vomiting, syncope as well as cardiogenic shock. However, Takotsubo cardiomyopathy usually occurs in association with a preceding physical or emotional stressful event(6,7). This is usually the case in more than 70% of the cardiomyopathies. In addition, unlike acute coronary syndrome (ACS) whereby peak occurrence of the symptoms usually occurs in the morning hours, the events in Takotsubo cardiomyopathy are usually predominant in the afternoon. This is because stressful prompts are likely to occur in the afternoon(1,8). Besides, patients with Takotsubo cardiomyopathy usually have minimal incidence of traditional risk factors for cardiovascular disease.

Cardiac angiography is the gold standard for diagnosing broken heart syndrome. On the other hand, a trans thoracic echocardiography is beneficial in diagnosing wall motion abnormalities which are usually present in Takotsubo cardiomyopathy(8). This includes hypo kinesis/akinesia of apical segment of left ventricle. However, as with any patient in whom acute coronary syndrome (ACS) is suspected, electrocardiography (ECG) should be the preliminary test undertaken shortly after presentation to the emergency department(3,9,10).

The authors present a case of Takotsubo cardiomyopathy in a young African female of Kenyan descent, with emphasis on their experience and outcome on the subject with the intention of eliciting the readers interest in this rare condition. TC is an uncommon myocardial condition that was once thought to be benign. However, lately TC has been reported that it may be associated with significant clinical consequences including death. In addition, the prevalence of broken heart syndrome might be underreported (11).

TC is documented to be present in 4-6% of female patients presenting with suspected ST elevation myocardial ischemia (STEMI). The mean age is between 65-70 years, while over 80% are above 50 years old. (12) The risk increases 10 times in women over 50yrs compared to men in the same age group. However, it is also important to note that incidence of TC has in children have been reported as well (13).

Moreover, the pathophysiology of TC still remains a puzzle. Some authorities have documented persistent underlying myocardial dysfunction despite the restoration on the left ventricular ejection fraction (14). Numerous theories have been described in an attempt to unravel the pathophysiology in TC. Catecholamine-induced myocardial injury is one of the well-recognized and well-known theory. However, it still does not illuminate all the clinical sequelae of this condition; giving rise to several other theories. This poor comprehension of pathophysiology of broken heart syndrome

has contributed to paucity of evidence-based interventions in its management, both in the acute setting as well as in prevention of major adverse cardiovascular events(10,15).

## 2.0 METHODOLOGY

On 13<sup>th</sup> December 2022, a 25-year-old Kenyan female presented to the largest teaching & referral hospital in Kenya with chest pain, dyspnea, palpitations, nausea and vomiting. The patient was received in the emergency room where she was stabilized, a battery of investigations ordered and ample history taken. The patient revealed that this was the third time she was presenting with the same symptoms over a span of 1 month and that the symptoms occurred mostly in the afternoons. She also confirmed that she had undergone a right above knee amputation a month earlier due to gangrene. She further intimated that she had a tumultuous marriage and her spouse had lately become abusive. She however had no cardiac risk factors. In addition, there was no familial history of cardiomyopathies or chronic diseases. This was her 4<sup>th</sup> admission to the hospital since birth. She reported to have received immunization according to the Kenya Expanded Program for Immunization (KEPI) Schedule. She had no food or drug allergies.

On physical examination, she looked anxious and was diaphoretic as well. She had a right above knee amputation stump that was due to dry gangrene, secondary to vascular obstruction. Her maximum temperature was 36.8, Pulse rate of 96 beats per minute, respiratory rate of 16, SPO2 of 90% at room air and Blood pressure of 83/54. She was well kempt. The left femoral pulse was present albeit reduced in volume. The foot felt warm up to the ankle joint, beyond which, the temperature was significantly reduced.

Despite the patient being hypotensive, the heart sounds were normal on auscultation. Most routine tests comprising complete blood count, Renal function tests, Liver function tests, antinuclear antibody test and triple serology were all normal. An ECG was done and indicated ST segment elevation. A transthoracic echocardiography was also done which showed wall motion abnormalities i.e. hypo kinesis of left ventricular apex as well as elevated ST segment, with a right atrium thrombus and left ventricle ejection fraction (LVEF) of 54%. However, there was no evidence of myocarditis. Cardiac angiography was done that also indicated regional wall motion abnormalities that extended beyond a single epicardial vascular distribution.

The cardiac enzymes (troponin I and troponin T) were elevated as well, which was consistent with myocardial infarction. A diagnosis of Takotsubo cardiomyopathy (a vaso-occlusive disease) with left ventricular apical clot cardio tubular phenomenon was made. She was admitted in one of the private wards for further management of the cardiomyopathy. Therapeutic levels of anticoagulation therapy with both heparin and warfarin were initiated on admission. The follow up echocardiograms performed after every 7 days later revealed progressive reduction in size of the thrombus, which had completely resolved at 4 weeks.

She was also put on oxygen, aspirin as well as b-blockers. 48 hours post admission, it was noted that the left 4<sup>th</sup> and 5<sup>th</sup> toes had suffered dry gangrene and had equally no sensation. Due to the reduced left femoral pulse volume as well as the dry left foot gangrene, a CT angiogram of the left lower limb was done, which indicated thrombus in the left popliteal artery. She was scheduled for disarticulation of the gangrenous toes and thromboembolectomy of the left popliteal artery by the orthopedic and cardiovascular surgeons respectively. The plastics team was brought on board for wound care while the physicians remained a crucial pillar in the management of the patient. This

was a patient being managed via multidisciplinary approach. Other specialties were also brought onboard on need basis.

The 25-year-old female underwent successful thromboembolectomy of the left popliteal artery and good flow was achieved after the procedure. She equally underwent successive debridement coupled with wound dressings of the left foot wound following disarticulation. She also developed right AKA stump wound sepsis, which necessitated serial debridement, systemic antibiotics and wound care. During the debridement, the femur length was also shortened so as to avoid protrusion beyond the skin margin. The choice of antibiotics administered was guided by wound swab culture which grew *E. coli* that was sensitive to Piperacillin/Tazobactam as well as Amoxicillin/Clavulanic acid; but resistant to Ampicillin, Cefazolin, Cefuroxime, Cefuroxime Axetil as well as Cefotaxime. The patient was put on Piperacillin/Tazobactam combination. The patient remained stable during the procedure. After debridement, the stump was dressed using VAC dressing, with continuous pressure of 80 mmHg. After a period of 5 days, the VAC dressing was removed then secondary closure of the stump done, tension free.

Nonetheless, 10 days post initial thromboembolectomy of the left popliteal artery, the left lower limb was noted to be cold with absent dorsalis pedis pulse, posterior tibia pulse as well as popliteal pulse. There were also ischemic skin changes coupled with loss of sensation to the level of the mid leg. An urgent CT angiogram was requested and showed occlusion of the left popliteal artery and left anterior tibia artery. She consequently underwent a left below knee amputation and primary closure of the stump. During the procedure, the muscles were noted to be healthy but had poor bleeding. The popliteal and tibia vessels were also noted to have been thrombosed. All these events took place in the background of therapeutic dosages of anticoagulants.

A post op CT angiogram of the left lower limb was done 5 days after the left leg below knee amputation procedure was done, when the limb was noted having lower temperature compared to the other limb. The CT angiogram revealed occlusion of the left femoral artery. She consequently underwent another successful thromboembolectomy of the left femoral vessel 24 hours later. During the procedure, it was noted that some sluggish back flow was obtained from the distal vessels despite having achieved good inflow. The patient continued with thrombolytic therapy 12 hours later. The patient was continued on anticoagulation therapy as well as broad spectrum antibiotic therapy. She was also put on Proton pump inhibitors (PPIs) as a prophylaxis against peptic ulcers formation. The limbs were also kept warm. Blood pressure lowering agents that the patient was put on included Enalapril, Aldactone and Bisoprolol. The patient also underwent counselling by professional counselors.

### **3.0 FINDINGS**

Follow up echocardiograms performed weekly revealed progressive reduction in size of the thrombus, which had completely resolved at 4 weeks. There was no more thrombi formation after thromboembolectomy of the left femoral artery. The stump sepsis was optimally managed using antibiotics that were informed by the culture results in addition to the satisfactory wound care. The patient generally responded positively to support medication administered as well. The support medication included Oxygen, beta blockers, aspirin as well as intravenous heparin. The wounds were healed and was discharged 4 weeks later, after undergoing series of counselling by a professional counsellor. There were no further complications. She was able to continue with her usual duties after discharge from the hospital.

## Discussion

At rest and during aerobic activity, the normal myocardium derives more than 80% of its energy from fatty acid metabolism(15). This route is usually inhibited during ischemia, and glucose is predominantly used instead, resulting in reduced myocardial performance. In spite of fairly normal myocardial perfusion in addition to nonexistence of ischemia in the left ventricular (LV) segments, patients with Takotsubo (stress) cardiomyopathy (broken heart syndrome) exhibit shift toward the glucose route(8,14,16).

A substantial physical, emotional or neurologic stressor/ injury usually heralds the development of the TC. some of these stressors include abusive relationship, surgery e.g. amputation of right above knee, serious accidents, natural disasters etcetera, which were also present in the current presentation(10). The revised Mayo clinic criterion for the diagnosis of Takotsubo cardiomyopathy dictates that the patient must have transitory hypo kinesis/dyskinesia/akinesia of left ventricle midsegments, absence of myocarditis, new ECG abnormalities e.g. elevated ST segments as well as absence of obstructive coronary disease(12). This criterion was met before the diagnosis of broken heart syndrome was made.

Because of the similarity to myocardial Infarction (MI), early treatments should concentrate on the management of coronary artery disease (CAD). As a result, the exclusion of CAD remains one of the diagnostic criteria for TC(8). As a result, administration of oxygen, aspirin, b-blockers as well as intravenous heparin, and are used as early treatments. Aspirin can be discontinued after ruling out CAD and additional confirmation of TC. When subjects with TC arrive at the hospital while in the acute stage, supportive as well as symptomatic care should be provided(5,6). Patients who are hemodynamically unstable may require cardiac assistance, uninterrupted venovenous hemofiltration, and an intra-aortic balloon pump.

Some writers have presented a unifying concept suggesting that neurohormonal stimulation causes abrupt myocardial dysfunction in susceptible people, particularly women, as shown via the distinctive LV wall-motion abnormalities of TC(8,10). It is however unclear if this is caused by spasms of various vessels, epicardial vessel blockage, thrombosis or direct myocardial toxicity.

Stress induced catecholamine's release has been documented as one of the most common mechanisms for TC. This release of catecholamine's is associated with toxicity to the myocardium and hence the ensuing stunning of the myocardium(12). Additionally, endomyocardial biopsies of subjects suffering from TC have established mononuclear infiltrates, reversible focal myocytolysis as well as contraction band necrosis. However, wall motion abnormality alone is deficient for the diagnosis of TC.

In as much as austere systolic dysfunction has been demonstrated in virtually all individuals with TC, it has equally been observed that intraventricular thrombus formation on the initial day of the disease presentation is uncommon(17). On the other hand, it has been established that the probability of under diagnosis of a thrombus can be prohibited by carrying out early ECG in TC. Most of the documented case reports describe cases that had intraventricular thrombus within the first fourteen days, hence underscoring the significance of follow up echocardiography at least 2 weeks later. The management of left ventricular thrombus in TC is largely debatable and in many cases warfarin and heparin are administered for a short duration.

Thrombotic events may worsen the course of Takotsubo cardiomyopathy, especially during the acute phase when LV function is still impaired as was the case with the current scenario(2). In

addition to blood stasis caused by cardiac stunning and localized hypo-/akinesia, endothelial activation and systemic hypercoagulability may enhance thrombus development in patients with TC. Furthermore, it is also imperative to note that patients with the typical form of broken heart syndrome appear to be particularly sensitive to ventricular thrombus development, most likely because to the greater volume of myocardium involved

The relationship between thrombotic events and broken heart syndrome is intricate. This is because it can be both a trigger as well as a complication of this condition(3,4). For example, thrombotic events such as arterial or venous thrombi can cause an acute Takotsubo cardiomyopathy episode, but they can also complicate the course of Takotsubo cardiomyopathy, as observed in the current study.

#### **4.0 CONCLUSION AND RECOMMENDATIONS**

##### **Conclusion**

TC is a rescindable type of cardiomyopathy that is associated with good prognosis and an exceptional morphological characteristic of the left ventricle, that is defined by apical inflating appearance that has been recognized for nearly a quarter a century. TC is otherwise known as stress cardiomyopathy because catecholamine drive is important in its development and pathology. Physical stress may also have an effect, leading to a wider range of TC characteristics. Symptomatic as well as supportive management still remains the core treatment with a focus on increasing left ventricle function for many days and complete recovery within 3-6 weeks. Suffice it to say, TC necessitates cautious diagnosis in addition to management because to its resemblance to myocardial infarction.

##### **Recommendations**

While ACEIs and ARBs may decrease TC relapse, the efficacy of beta blockers has not been determined. We also recommend that patients with identified LV thrombus ought to be anticoagulated till LV function normalizes in addition to the thrombus no longer being present on echocardiogram. Administration of chronic beta-blocker treatment could possibly decrease the probability of repeated episodes

## REFERENCES

1. Takotsubo (Stress) Cardiomyopathy (Broken Heart Syndrome): Background, Pathophysiology, Etiology [Internet]. [cited 2023 Aug 9]. Available from: [https://emedicine.medscape.com/article/1513631overview?&icd=login\\_success\\_email\\_mateh\\_fpf](https://emedicine.medscape.com/article/1513631overview?&icd=login_success_email_mateh_fpf)
2. Herath HMMTB, Pahalagamage SP, Lindsay LC, Vinothan S, Withanawasam S, Senarathne V, et al. Takotsubo cardiomyopathy complicated with apical thrombus formation on first day of the illness: a case report and literature review. *BMC Cardiovasc Disord* [Internet]. 2017 Jul 3 [cited 2023 Aug 3];17(1). Available from: <https://pubmed.ncbi.nlm.nih.gov/28673245/>
3. de Gregorio C, Grimaldi P, Lentini C. Left ventricular thrombus formation and cardioembolic complications in patients with Takotsubo-like syndrome: a systematic review. *Int J Cardiol* [Internet]. 2008 Dec 17 [cited 2023 Aug 3];131(1):18–24. Available from: <https://pubmed.ncbi.nlm.nih.gov/18692258/>
4. Cammann VL, Sarcon A, Ding KJ, Seifert B, Kato K, Di Vece D, et al. Clinical Features and Outcomes of Patients With Malignancy and Takotsubo Syndrome: Observations From the International Takotsubo Registry. *J Am Heart Assoc*. 2019 Aug 6;8(15).
5. Takotsubo Cardiomyopathy: A Brief Review - PubMed [Internet]. [cited 2023 Aug 3]. Available from: <https://pubmed.ncbi.nlm.nih.gov/32341693/>
6. Minciullo PL, Amato G, Vita F, Pioggia G, Gangemi S. ATAK Complex (Adrenaline, Takotsubo, Anaphylaxis, and Kounis Hypersensitivity-Associated Coronary Syndrome) after COVID-19 Vaccination and Review of the Literature. *Vaccines* [Internet]. 2023 Jan 31 [cited 2023 Aug 3];11(2). Available from: <http://www.ncbi.nlm.nih.gov/pubmed/36851200>
7. Chow LTC, Chow MBCY. Coronary artery myointimal dysplasia in patients with pheochromocytoma—possible causal relationship: pathophysiology and clinical implication with reference to Takotsubo cardiomyopathy and spontaneous coronary dissection. *Cardiovasc Pathol*. 2018 Nov 1;37:45–53.
8. Matta AG, Carrié D. Epidemiology, Pathophysiology, Diagnosis, and Principles of Management of Takotsubo Cardiomyopathy: A Review. *Med Sci Monit*. 2023;29.
9. Angelini P, Uribe C. Is Transient Takotsubo Syndrome Associated With Cancer? Why, and With What Implications for Oncocardiology? *J Am Heart Assoc*. 2019 Aug 6;8(15).
10. Amin HZ, Amin LZ, Pradipta A. Takotsubo Cardiomyopathy: A Brief Review. *J Med Life* [Internet]. 2020 [cited 2023 Aug 3];13(1):3–7. Available from: <https://pubmed.ncbi.nlm.nih.gov/32341693/>
11. Ghadri J-R, Shor Wittstein I, Prasad A, Sharkey S, Dote K, John Akashi Y, et al. International Expert Consensus Document on Takotsubo Syndrome (Part I): Clinical Characteristics, Diagnostic Criteria, and Pathophysiology. *Eur Heart J* [Internet]. 2018;39:2032–46. Available from: <https://academic.oup.com/eurheartj/article/39/22/2032/5025412>
12. Ghadri JR, Wittstein IS, Prasad A, Sharkey S, Dote K, Akashi YJ, et al. International Expert Consensus Document on Takotsubo Syndrome (Part I): Clinical Characteristics, Diagnostic Criteria, and Pathophysiology. *Eur Heart J* [Internet]. 2018 Jun 7 [cited 2023 Aug



- 9];39(22):2032–46. Available from: <https://pubmed.ncbi.nlm.nih.gov/29850871/>
13. Dias A, Núñez Gil IJ, Santoro F, Madias JE, Pelliccia F, Brunetti ND, et al. Takotsubo syndrome: State-of-the-art review by an expert panel – Part 1. *Cardiovasc Revascularization Med.* 2019 Jan 1;20(1):70–9.
  14. Pathophysiology of Takotsubo Syndrome - StatPearls - NCBI Bookshelf [Internet]. [cited 2023 Aug 9]. Available from: <https://www.ncbi.nlm.nih.gov/books/NBK538160/>
  15. Khalid N, Ahmad SA, Shlofmitz E, Chhabra L. Pathophysiology of Takotsubo Syndrome. *StatPearls* [Internet]. 2023 Mar 6 [cited 2023 Aug 9]; Available from: <https://www.ncbi.nlm.nih.gov/books/NBK538160/>
  16. Tanabe Y, Akashi YJ. Improving the understanding of Takotsubo syndrome: consequences of diagnosis and treatment. *Expert Rev Cardiovasc Ther.* 2016 Jun 2;14(6):737–48.
  17. Pelliccia F, Kaski JC, Camici PG. Takotsubo syndrome’s pathophysiology: Still a mystery? *Eur Heart J.* 2019 Jun 21;40(24):1989.