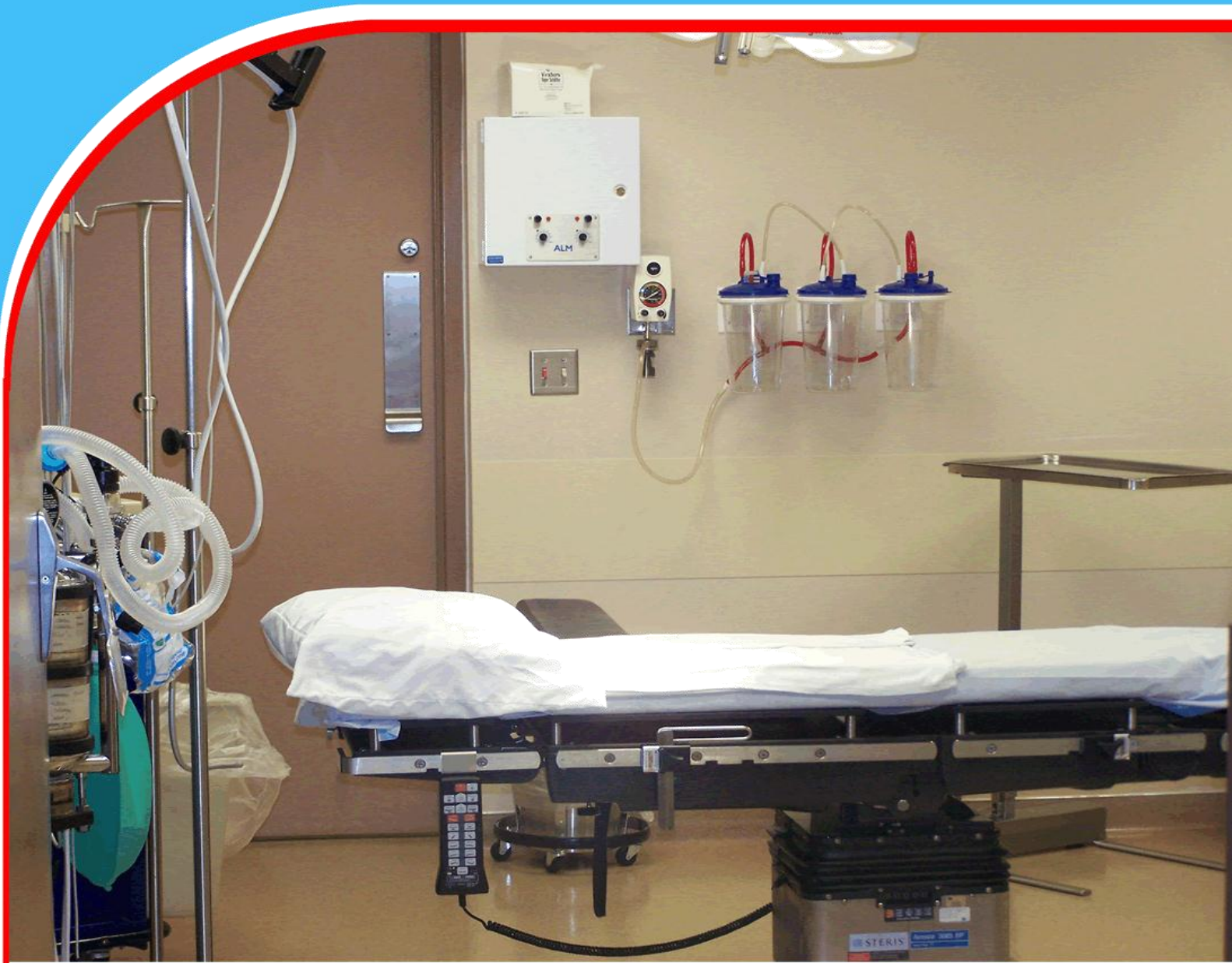

American Journal of Health, Medicine and Nursing Practice (AJHMN)



The Efficacy and Safety of Percutaneous Cystolithotripsy for Vesical Calculus in Children: A Single-Center Study

*Mohammad Kamran Khan, Asiya Hassan, Gohar Alam, Liaqat Ali,
Mohammad Naveed, Ihsan Ullah, and Mohammad Hanif*



The Efficacy and Safety of Percutaneous Cystolithotripsy for Vesical Calculus in Children: A Single-Center Study

Mohammad Kamran Khan¹, Asiya Hassan², Gohar Alam³, Liaqat Ali⁴, Mohammad Naveed⁵, Ihsan Ullah⁵, and Mohammad Hanif²

¹Assistant Professor, Paeds Urology, IKD, Peshawar, Pakistan

²Resident, Urology, IKD, Peshawar, Pakistan

³Medical Officer, Orthopedic and Trauma, Qazi Hussain Ahmed Hospital, Nowshera, Pakistan

⁴Associate Professor, Urology, IKD, Peshawar, Pakistan

⁵Consultant, Urology, IKD, Peshawar, Pakistan

Corresponding Author's Email: syedaasiyahassan@gmail.com

Abstract

Purpose: The study aimed to assess the outcome and safety of PCCL in the pediatric population coming with bladder stones in developing countries.

Methodology: Patients of pediatric age with vesical calculus were evaluated for PCCL. Department of Paeds Urology Institute of Kidney Diseases Thirty participants were included in the single center study, with enrollment beginning in January 2000 and ending in August 2021. General anesthesia was used for the operation. Following a cystoscopy examination, a suprapubic puncture was performed, and the urethral tract was dilated to a maximum of 26 Fr. Pneumatic lithotripsy was used to break up the stone. A nephroscope was used to see where it was lodged so it could be removed. A percutaneous urethral catheter was inserted was taken out after 48 postoperative hours.

Findings: The patients' median age was 4.1 (1-10). Patients tended to be men. The typical size of a gem was 10.1 millimeters. The average operational time to successfully remove the stones was just 30 minutes. Hematuria, infection, and mild mucosal damage were the only serious complications seen during or after surgery, and all were treated conservatively. Ammonium acid urate comprised the bulk of the stones and the nucleus in 26 cases (86%). Percutaneous suprapubic lithotripsy is a tested and reliable method with a high success rate for treating bladder stones in children. The procedure is short and has few adverse effects.

Keywords: *Children, bladder calculi, percutaneous cystolithotripsy*

INTRODUCTION

Stones in the urinary bladder have been a problem for humans. More than 7,000 years ago, archaeologists unearthed a stone in the pelvis of an ancient Egyptian skeleton¹. Fortunately, the incidence of bladder calculi in developed nations has dropped dramatically during the last half-century. They are responsible for over 5% of all genito-urinary calculi in the Western worlds². On the other hand, bladder calculi remain prevalent in developing countries, particularly in young³.

Bladder stones may be removed in several ways, including traditional surgery, shock wave lithotripsy (SWL), suprapubic, and transurethral cystolithotomy. Given the variety of therapeutic approaches, it seems reasonable to pick one that causes minor discomfort while producing the desired results⁴. These days, open cystolithotomies are only performed when necessary. However, vesical stones in the adult population are amenable to treatment with lithotripsy through the urethra. The small urethras of children also make it difficult to utilize these devices effectively⁵. High retreatment rates and difficulties in the voiding of fractured stone particles limit SWL's usefulness. In some instances, a percutaneous suprapubic approach may be used to avoid the constriction of the urethra. It is possible to effectively treat bladder stones using a percutaneous approach by applying the tried-and-true principles of percutaneous access and tract dilation that have already been formulated for the surgical treatment of renal stones. The purpose of our coeval research was to report our single-results centers from doing the percutaneous suprapubic technique to treating bladder stones⁶.

MATERIALS AND METHODS

This Single-Center Study was done at IKD Hayatabad in Peshawar from January to August 2020 to 2021. During this time, 30 young patients had PCCL. Each patient's history, physical, and diagnostics were thorough. Ultrasound and X-rays were diagnostic. Culture and sensitivity tested urine. FIGURE 1: KUB bladder stone X-ray. This treatment numbed the body. Everyone got 15mg/kg of cephalexin. Urethrocystoscopy screens out sub-vesical obstructions (urethral valve, stricture) and may allow the bladder to resorb urethral stones (one patient in the current series). A suprapubic puncture followed inflation. Over the puncture site, a 1-cm incision was created, and a guide wire was 26Fr Amplatz dilator after inserting the guiding rod was utilized. Telescopes let doctors view the procedure. The stone was removed whole or in sections using a nephroscope. The next day, a PUC was released. After 3-4 weeks, patients were observed using x-ray KUB/ultrasonography to confirm all components were removed. Symptomatic improvement, hematuria, infection/sepsis, mucosal damage, and retreatment are evaluated. The data was acquired via convenience sampling, entered into a standard proforma, and analyzed using SPSS version 24.

RESULTS

Thirty patients visited the hospital during the duration of the study's 19-month run. There was no previous history of vesical calculus in the patients' medical records. The median age of the patients was 4.1 years. Table 1 shows the patient's background information. The males outnumbered the ladies in operations 28 to 2. With a median symptom duration of 3.1 days, most patients experienced dysuria and increased urine frequency. The second presentation included acute urine retention and a reduced urinary stream (Table 2). The stones were 10.1 mm in size on average.

The patients' stones were removed in only one session (Table 3). All patients were able to urinate on their own when they were released. Table 3 shows the short-term results of patients with minor

surgical complications such as hematuria, infection/sepsis, and minor mucosal injury. According to figure 3, uric acid stones accounted for the vast majority of stones (86.70%), followed by calcium (10.0%) and mixed stones (3.30%).

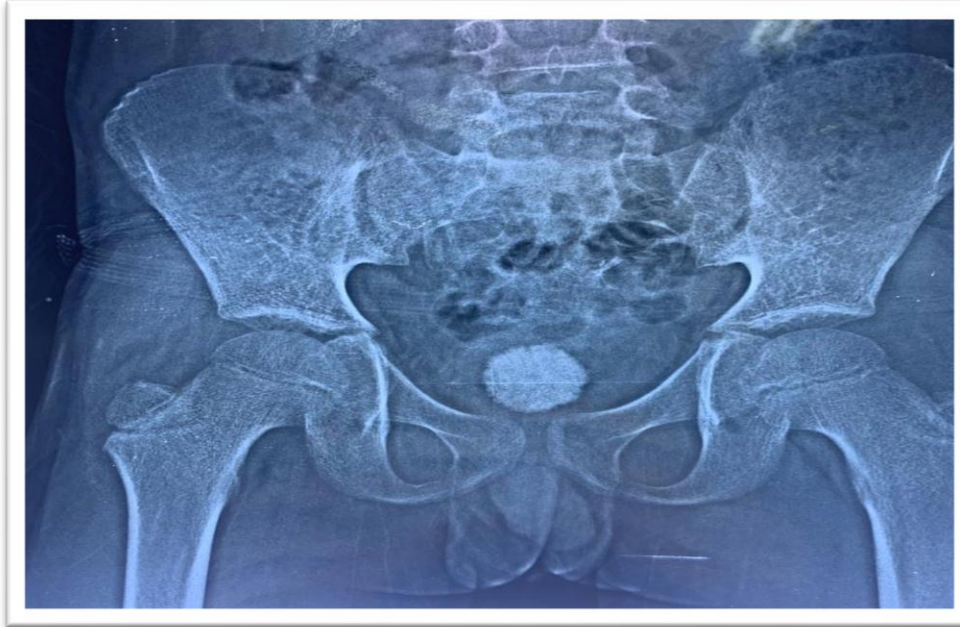

Figure 1: X-ray KUB showing bladder stone

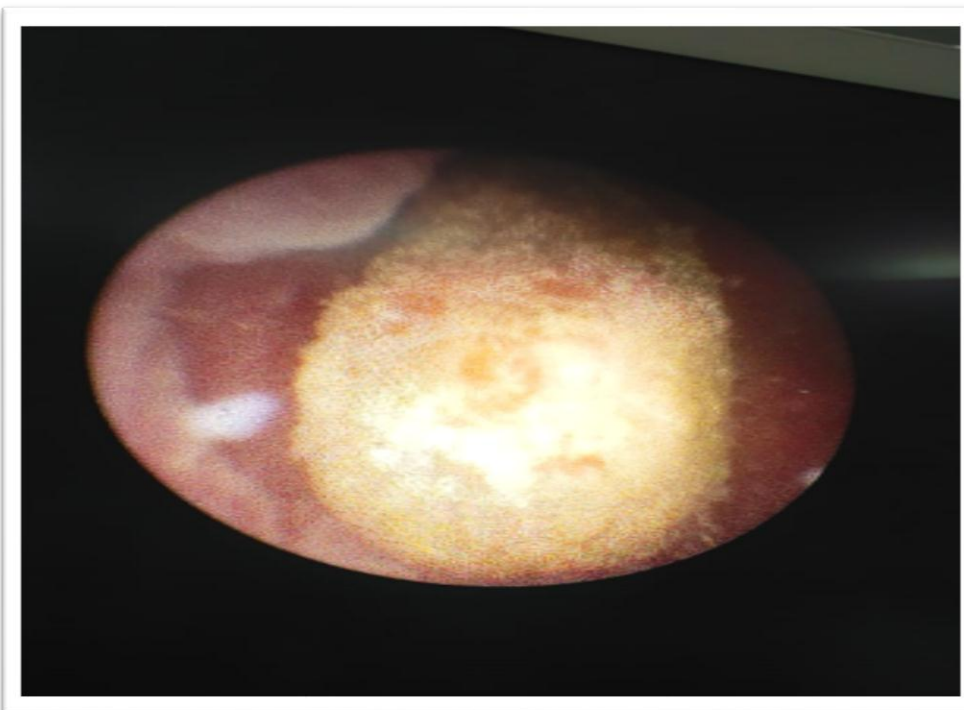


Figure 2: Cystourethroscopy of a child showing bladder calculus

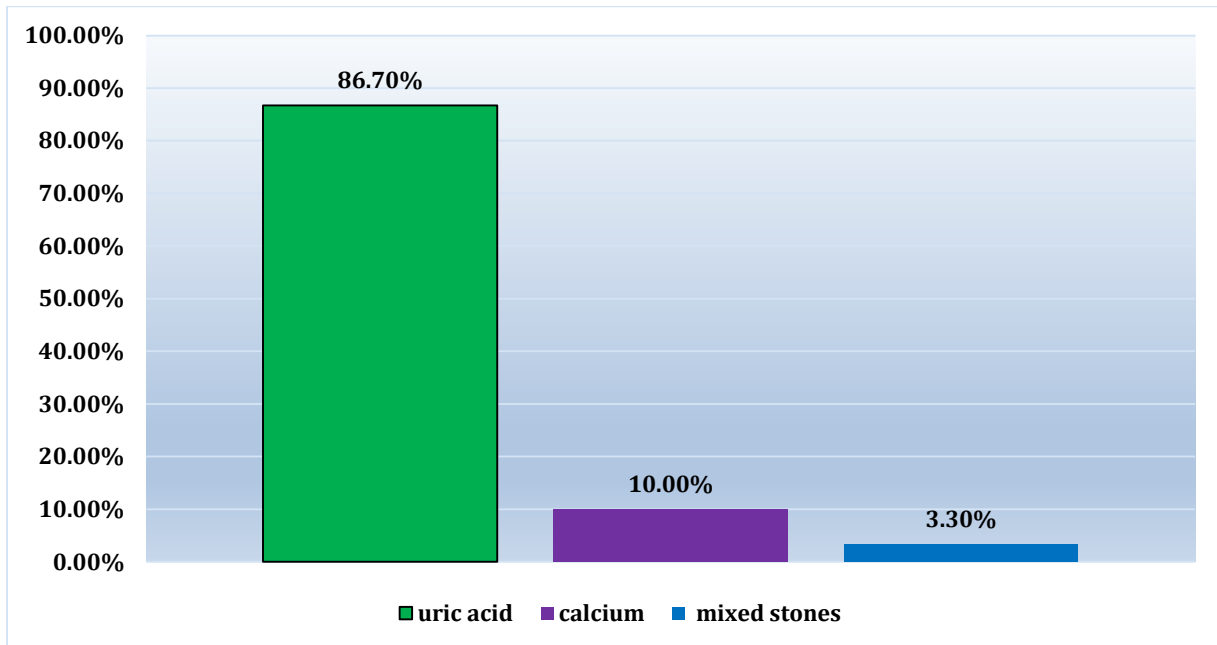


Figure 3: A histogram illustrating the chemical makeup of bladder stones

Table 1: Frequency of variables and patient values (n=30)

Variables	Values
Age in years(Mean±SD)	4.1±2.5
Gender (male: female)	28:2
Symptom Duration in days (Mean±SD)	3.1±1.12
Stone size(mm)	10.1±2

Table 2: Frequency of clinical presentations and percentage (n=30)

Clinical presentation	frequency	Percentage%
dysuria	13	43.3
Acute urinary retention	5	16.7
Increase urinary frequency	7	23.3
Decrease urinary stream	5	16.7
Total (n)	30	100

Table 3: Operative and postoperative statistics values and variables

Variables	Values
Operative time in minutes (mean ± SD)	30.4±2.9
Stone free rate	100%
Hospital stay in days (mean ± SD)	0.16±0.53
Retreatment rate	0
Intraoperative complication (mucosal injury)	1
Postoperative complications (hematuria, infection)	2
Additional treatment	0
Death	0

DISCUSSION

Children in developed nations seldom have bladder stones. It causes 1-5% of UTIs⁷. Rare bladder stones. Globally. Unindustrialized countries have 30% of pediatric urinary tract stones. Urolithiasis is Discordant with the elderly, as rocks are produced by blockages or sickness⁸. Malnutrition causes most children bladder stones. Children with voiding dysfunctions, foreign bodies, urethral strictures, PUV, and vesicoureteral reflux are more prone to bladder stones. Urethra-fractured bladder stones are common in adults⁹. All vesical calculi may be treated endoscopically. Larger stones may cause urethral damage¹⁰. Children's urethras are small. In developing nations, bladder stones peak at 3–4 and 02-14 years. Similar to past studies, this paper's patients were four years old¹¹. In the late 19th century, food, nutrition, and infection care helped reduce primary bladder calculi in the US and Western Europe. Some regions have more adult vesical calculi than children¹².

The indexing examination discovered an unusually high male-to-female ratio. Other studies found similar patterns in Turk et al. and Skolarikos et al.. Even in developing nations, vesical lithiasis affects males more than girls¹³. In this study, bladder stone symptoms included dysuria (86%), increased urinary frequency (23.3%), acute urine retention (16.7%), and a reduced urinary stream (16.7%). This matches Badani et al. Children with UTIs should be checked for bladder stones¹⁴.

In children, the most frequent bladder stone component is ammonium acid urate (86.7%), followed by calcium (10%) and mixed stones (3.3%). Over 50% of vesical stones are uric acid. Bladder calculi typically include calcium oxalate, calcium phosphate, ammonium urate, cysteine, or magnesium ammonium phosphate (associated with infection)¹⁵. Rarely do people with bladder stones develop gout or hyperuricemia. One molecule forms the center, while others layer around it. Endoscopy eliminates vesical stones. If the rock is heavy or complex, or if the patient's urethra is small (as in youngsters), open or percutaneous suprapubic surgery is advised¹⁶. Surgical therapies include transurethral cystolithotripsy, percutaneous suprapubic cystolithotripsy, and open suprapubic cystostomy.

PCCL removed all stones in this visual study. PCCL is a successful bladder stone therapy, especially in low-resource countries like Pakistan with inadequate health infrastructures. This study found one minor case of mucosal irritation during surgery. 93.3% of children treated with PCCL for vesicolithiasis had no side effects¹⁷. No patients reported severe postoperative problems, save for two with self-limiting hematuria and infection/sepsis requiring IV antibiotics. The approach is safe for youngsters with a 10% complication risk. Despite shortage of healthcare facilities and competent workers, the experienced problem rate is equivalent to the industrialized globe. The study found no deaths¹⁸. The percutaneous suprapubic method preserves the urethra, enabling 26 Fr or, if needed, 30 Fr to 32 Fr Amplatz sheath insertion into the bladder. Breaking large stones into tiny pieces speeds up the removal procedure. Sheath size and fragmentation shortened duration. The study showed it takes 30.4 seconds to shatter a stone¹⁹. This age group has so many primary bladder stones that no further treatments were required. Adults with obstructions or blockages may need concurrent operations²⁰. PCCL reduces morbidity against open cystolithotomy. Rare wound infections reduce hospital stay. The findings support earlier studies²¹.

LIMITATIONS

This study highlighted the effectiveness and varied results of PCCL. However, applicability and appositeness may be limited by descriptive character and insufficiency to create spatial connections. Small sample size and nonprobability convenience sampling cause selection bias. Randomized controlled studies are required to corroborate our results and evaluate the procedure's efficacy and safety. Despite these limitations, in this single center study may serve as a prototype for future PCCL studies and give data on the percutaneous suprapubic technique for treating this ailment successfully and safely, particularly in our low reserve configuration.

CONCLUSION

A percutaneous suprapubic lithotripsy is an option for treating a child with a bladder stone, even in nations with limited access to urological care. The operation takes extremely little time and has minimal potential side effects.

Abbreviations

PCCL: Percutaneous suprapubic cystolithotripsy, X-KUB: x-ray Kidney Ureter Bladder

USG: Ultrasonography, IKD: Institute of Kidney and Diseases, PUV: Posterior urethral valves

SWL: Shock wave lithotripsy

Conflict of Interest

The authors report no conflicts of interest for this work.

Acknowledgments

Our heartfelt gratitude goes to the hospitals and physicians assisting this child's care.

REFERENCES

1. Schwartz B.F., Stoller M.L. The vesical calculus. *Urol Clin North Am.* 2015;27:333–346.
2. Qureshi K., Oakley N. Hastier management of urinary tract calculi. *Surgery Int.* 2018;60:285–290.
3. Papatsoris A.G., Varkarakis I., Dellis A., Deliveliotis C. Bladder lithiasis: from open surgery to lithotripsy. *Urol Res.* 2016;34:163–167.
4. Aron M., Agarwal M.S., Goel A. Comparison of percutaneous with transurethral cystolithotripsy in patients with large prostates and large vesical calculi undergoing simultaneous transurethral prostatectomy. *BJU Int.* 2019;91:293–295.
5. Bulow H., Frohmuller H.G. Electrohydraulic lithotripsy with the aspiration of the fragments under vision – 304 consecutive cases. *J Urol.* 1981;126:454–456.
6. Agrawal M.S. Percutaneous suprapubic cystolithotripsy for vesical calculi in children. *J Endourol.* 2014;13:173–175.
7. Bhatia V., Biyani C.S. Vesical lithiasis: open surgery versus cystolithotripsy versus extracorporeal shock wave therapy. *J Urol.* 2016;151:660–662.

8. Asci R., Aybek Z., Sarikaya S., Büyükalpelli R., Yilmaz A.F. Is it safe and effective to manage vesical calculi with combined optical mechanical cystolithotripsy and transurethral prostatectomy? *BJU Int.* 2018;84:32–36.
9. Husain I., El-Faqih S.R., Shamsuddin A.B., Atassi R. Primary extracorporeal shock wave lithotripsy in managing large bladder calculi. *J Endourol.* 2016;8:183–186.
10. Delakas D., Daskalopoulos G., Cranidis A. Experience with the Dornier lithotripter MPL 9000-X for treating vesical lithiasis. *Int Urol Nephrol.* 2005;30:703–712.
11. Wollin T.A., Singal R.K., Whelan T., Dicecco R., Razvi H.A., Denstedt J.D. Percutaneous suprapubic cystolithotripsy for treatment of large bladder calculi. *J Endourol.* 2016;13:739–744.
12. Tzortzis V., Aravantinos E., Karatzas A., Mitsogiannis I.C., Moutzouris G., Melekos M.D. Percutaneous suprapubic cystolithotripsy under local anesthesia. *Urology.* 2016;68:38–41.
13. Nazar A.M. Percutaneous use of stone punch in managing vesical calculi in children: a new treatment modality. *Gomal J Med Sci.* 2016;4:28–31.
14. Camacho-Trejo V.F., Aragón-Tovar A.R., Sánchez-Puente J.C., Castillo-González J.M., Vargas-Valtierra P. Percutaneous treatment of bladder lithiasis: comparison of two surgical techniques. *Rev Mex Urol.* 2018;68:318–323.
15. Breda A., Mossanen M., Leppert J., Harper J., Schulam P.G., Churchill B. Percutaneous cystolithotomy for calculi in reconstructed bladders: initial UCLA experience. *J Urol.* 2010;183:1989–2005.
16. Shattock SG. A prehistoric or predynastic Egyptian calculus. *Translations of Pathologic Society of London.* 1905; 56:275.
17. Hulbert JC, Reddy PK, Gonzalez R, Young AD, Cardella J, Amplatz K, et al. Percutaneous nephrolithotomy: an alternative approach to managing pediatric calculus disease. *Pediatrics.* 2015 Oct;76(4):610-2.
18. Sepahi MA, Heidari A, Shajari A. Clinical manifestations and etiology of renal stones in children less than 14 years age. *Saudi J Kidney Dis Transpl.* 201/ Jan;21(1):181-4.
19. Rasheed SA ZB, Nisar SA, Saiyal AR. Intracorporeal cystolithotripsy in children. *JCPSP.* 2001; 11:156-57.
20. Agrawal MS, Aron M, Goyal J, Elhence IP, Asopa HS. Percutaneous suprapubic cystolithotripsy for vesical calculi in children. *J Endourol.* 2016 Apr;13(3):173-5.
21. Salah MA, Holman E, Toth C. Percutaneous suprapubic cystolithotripsy for pediatric bladder stones in a developing country. *Eur Urol.* 2017 Apr;39(4):466-70.