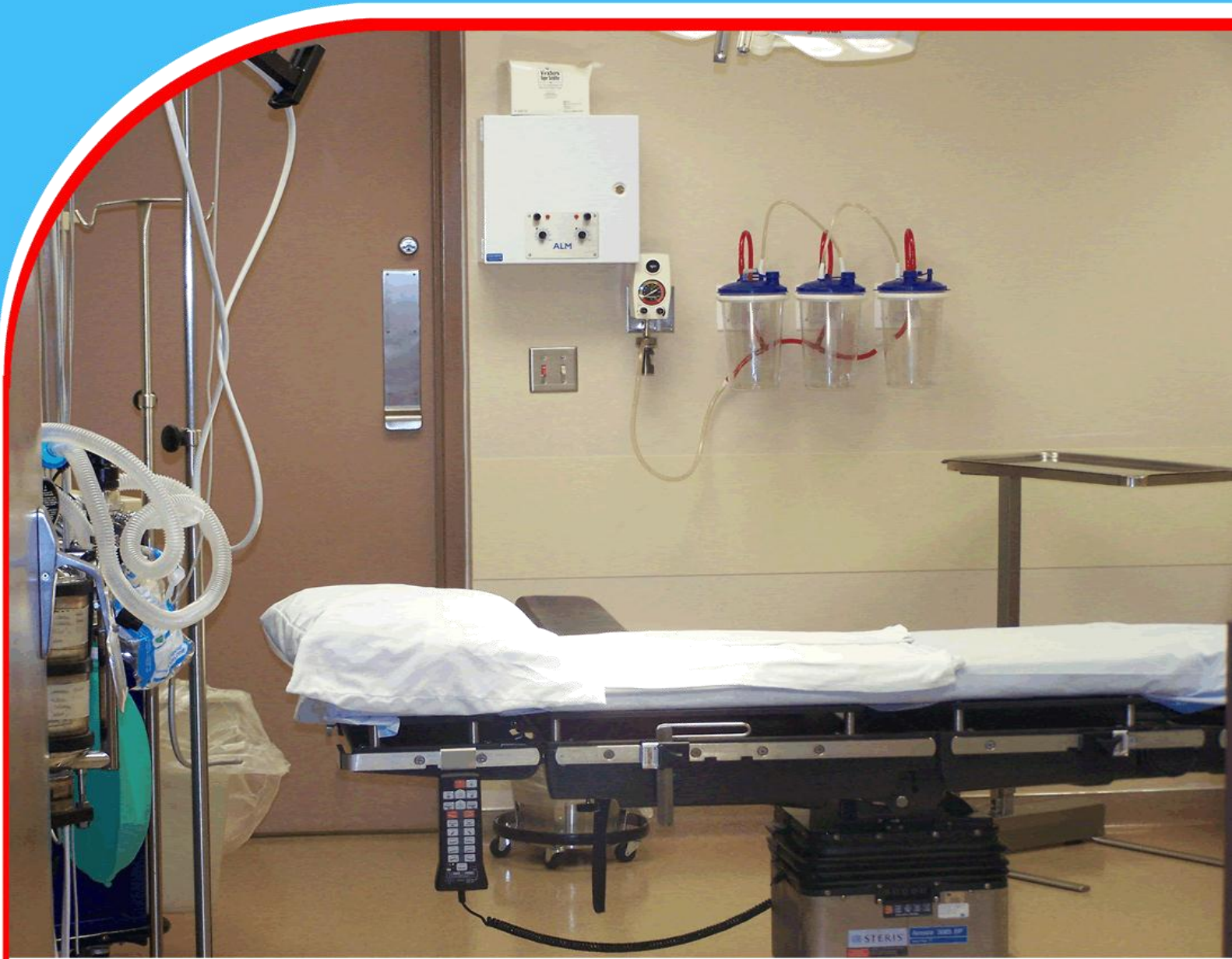

American Journal of Health, Medicine and Nursing Practice (AJHMN)



Circumportal Pancreas - A Rare Case

*Dr. Muhammad Mehraiz Khan, Dr. Anish Kumar, Dr. Faisal Ehsan
Cheema, Dr Hafiz Fahad Ullah Saeed, and Dr. Jawairia Arif*



Circumportal Pancreas - A Rare Case

Dr. Muhammad Mehraiz Khan

Institute of Nuclear Medicine and Oncology (INMOL), Lahore, Pakistan.

Email: mehraizkhan2015@gmail.com

Dr. Anish Kumar

Ghulam Mohammad Mahar medical college, Sukkur, Pakistan.

Email: anishparmaniii@gmail.com

Dr. Faisal Ehsan Cheema

Institute of Nuclear Medicine and Oncology (INMOL), Lahore, Pakistan.

Email: fecheema@gmail.com

Dr Hafiz Fahad Ullah Saeed

King Edward Medical University, Mayo Hospital, Lahore, Pakistan.

Email: fahadullah008@gmail.com

Dr. Jawairia Arif

Institute of Nuclear Medicine and Oncology (INMOL), Lahore, Pakistan.

Email: jawairia213@gmail.com

Abstract

Circumportal pancreas is a rare anatomical variant in which anomalous pancreatic parenchyma entirely encircles the portal vein. A 60 years old female presented to us for CT enteroclysis with complaint of diffuse abdominal pain. Infraplenic circumportal pancreas with anteportal pancreatic duct was reported, which is an incidental finding. It presents a diagnostic challenge for a radiologist because misinterpretation of circumportal pancreas as a pancreatic head mass can have a significant impact on clinical outcomes i.e. postoperative pancreatic fistula and can help surgeon to plan better approach for pancreatectomies.

Keywords: *Circumportal pancreas, portal vein, post-operative pancreatic fistula*

Introduction

Pancreas is a retroperitoneal organ that helps in the digestion and controls the body's blood glucose level. During the fourth week of gestation, it develops as dorsal and ventral pancreatic buds from endodermal cells of the caudal part of the foregut. The ventral pancreatic bud is a precursor of uncinata process and caudal part of the head while the rest of pancreas originates from the dorsal pancreatic bud. The ventral pancreas fuses with the dorsal pancreas by the end of the sixth week. At this time, ducts also anastomose; giving rise to main pancreatic duct and an accessory pancreatic duct [1]. Therefore, during the intrauterine life, this whole process of pancreatic development is complex and results in a broad range of congenital malformations.

Pancreas and pancreatic duct related anomalies, including some normal variants are often reported as coincidental findings in asymptomatic individuals. Ectopic pancreas, annular pancreas, pancreatic divisum, circumportal pancreas, and variations of pancreatic ducts are some of the known anomalies and variants [2]. Pancreatic divisum is the most frequently known congenital disorder of the pancreas, occurring in approximately 10 % of human beings [3]. Circumportal pancreas is a rare annular variant with a prevalence of 1.1-2.5 %, in which the portal vein or splenoportal confluence is bordered by the pancreatic tissue [4]. It makes resection of the pancreatic head difficult and also the pancreaticojejunal anastomosis. Thus, requiring extensive dissection. Post-operative pancreatic fistula is a common complication during pancreatectomies in patients with circumportal pancreas, which can be monitored by peritoneal drain amylase levels [3].

Case Presentation

A 65 years old female presented to radiology department INMOL Hospital for CT enteroclysis as advised by her physician. She had a history of mild recurrent abdominal pain for the last 6 months. Pain was post prandial and non-radiating. There were pain free episodes in between. She took medications (proton pump inhibitors) for the complaint but the pain was not relieved. There were no altered bowel habits. No hematemesis or melena. The patient was non-hypertensive and non-diabetic. There was no history of alcohol intake. No history of trauma existed. Her complete blood count, renal function and liver function tests were performed which were within normal limits, except for the mildly raised AST (45 U/L). An outside ultrasound report was available, which was unremarkable.

Her CT enteroclysis was performed in the department which revealed pancreatic parenchyma surrounding the portal vein like an annulus occupying an infraplenic location (as shown in figure 1A and 1B) and the pancreatic duct was coursing anterior to the portal vein (as shown in figure 2A and 2B). These findings are suggestive of infra splenic circumportal pancreas with anteportal pancreatic duct (type III B). The pancreas otherwise appears normal. Pancreatic duct was of normal caliber. Portal vein was normal. There was no evident bowel related mass appreciated. The patient was reassured and was referred back to her physician.

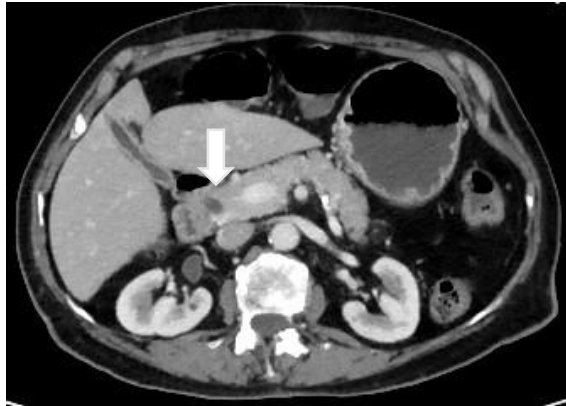


Figure 1A: CT enteroclysis (A) axial slice.

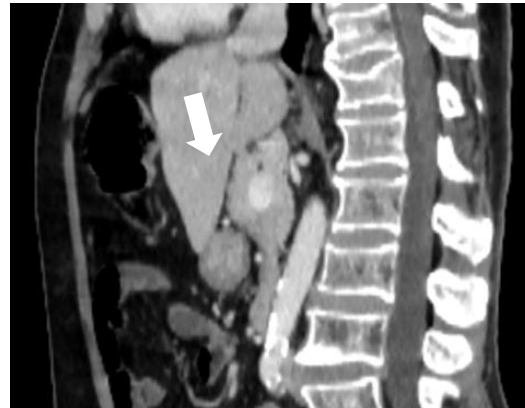


Figure 1B: Sagittal view of 65 years old patient showing pancreatic tissue completely encircling the portal vein, representing circumportal pancreas

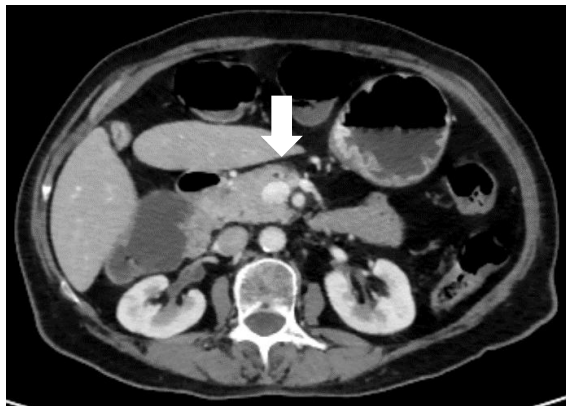


Figure 2A: CT enteroclysis axial slice

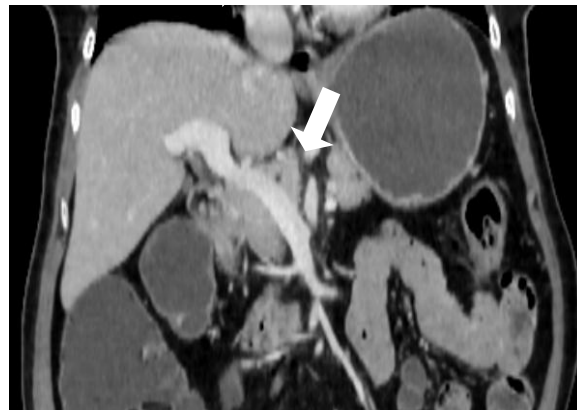

Figure 2B: Coronal view of same patient shows the anterior course of pancreatic duct in relation with portal vein i.e anteportal

Discussion

Throughout the medical community, there are many variants of normal anatomy involving multiple organ systems. Therefore, congenital abnormalities and anatomic variants of the pancreas are not uncommon and appear in a variety of ways. However, they may remain undetected until adolescence are frequently reported as an accidental finding in asymptomatic individuals. So congenital pancreatic anomalies should be considered in the patients who present with prolonged and irrational complaints of abdominal discomfort i.e nausea, vomiting, and pain [5].

Fusion anomalies of the pancreas are of three types: annular pancreas, pancreatic divisum, and circumportal pancreas [6]. One of the most important and rare congenital disorder of the pancreas is circumportal pancreas. Although most common in the porcine pancreas, it is rare in the human population with a prevalence rate of 1.1 to 2.5 % without gender specification [7]. It is postulated

that during embryogenesis, an abnormal fusion of uncinata process with the body of the pancreas to the left of portomesenteric confluence and thus encircling it is the cause of circumportal pancreas [8]. The first case was reported by Sugiura et al. in 1987 as an enlargement of the uncinata process of pancreas and encasing of the portomesenteric confluence [4]. It is a subclinical condition and a coincidental finding in imaging. A surgeon may come across it while performing pancreatic surgery [7,8]. Even though magnetic resonance cholangiopancreatogram is diagnostic in the evaluation of pancreas and especially pancreatic duct related anomalies, this anatomical variant can easily be recognized on contrast enhanced computed tomography [4,8].

Based on the route of the major pancreatic duct with the portal vein, Joseph et al. in a study classified the circumportal pancreas into three main types. In type I, the pancreatic duct courses posterior to the portal vein (retroportal). Type II represents a combination of type I along with pancreatic divisum, while in type III pancreatic duct courses anterior to the portal vein (anteportal). In another study, Karasaki et al. further classified it depending on the relation of fused aberrant pancreatic tissue to the splenic vein as: type A is suprasplenic, type B is intrasplenic, and type C is a mixed type [9]. However, the most familiar type of circumportal pancreas is type IIIA (prevalence of 44.4–82%) followed by type IA (prevalence of 5–27.8%) [7].

Patients diagnosed with circumportal pancreas, approximately 31% of the patients also have vascular variations. This includes celiac trunk variants or an aberrant common, right or left hepatic artery e.g intrapancreatic course of the common hepatic artery or right and left hepatic arteries originating from the superior mesenteric artery and left gastric artery respectively [7]. Despite the scarcity of this anatomical variant, it should be a matter of interest for clinicians and surgeons for several reasons. Firstly, it may be overlooked on pre-operative imaging and may be misinterpreted as periportal lymphadenopathy, enlargement of the caudate lobe of the liver, pancreatic mass encircling the portal vein, or post-operative residual mass leading to many undesired surgeries, as it happened in the past [4]. Secondly, circumportal pancreas has also been linked with an increased incidence of postoperative pancreatic fistula following pancreatectomies with prevalence rate of 44 to 46 % [4,8]. Lastly, as discussed above the circumportal pancreas may be associated with various vascular disparities (prevalence of 31%). Detrimental outcomes result in cases of accidental ligation secondary to improperly addressed intra-operative findings [4,7].

Conclusion

Circumportal pancreas is a rare congenital anatomical variant usually identified as an incidental finding on imaging. It is an asymptomatic condition and has no relation to postprandial pain. However, its diagnosis is crucial as it is one of the leading causes of postoperative pancreatic fistula. So, a radiologist must be keen while reporting as his diagnosis will aid the surgeon to plan better for the pancreatectomies and to avoid complications.

References

1. Kim SS, Shin HC, Hwang JA. Various congenital abnormalities and anatomic variants of the pancreas: A pictorial review. *Journal of the Belgian Society of Radiology*. 2019;103(1).
2. Yu J, Turner MA, Fulcher AS, Halvorsen RA. Congenital anomalies and normal variants of the pancreaticobiliary tract and the pancreas in adults: part 2, Pancreatic duct and pancreas. *American Journal of Roentgenology*. 2006 Dec;187(6):1544-53.

3. Ehrhardt JD, Gomez F. Embryology, Pancreas.
4. Kabir T, Xuan ZT, Chung AY. Circumportal pancreas: A report of two cases. *Annals of Hepato-biliary-pancreatic Surgery*. 2019 Aug 1;23(3):300-4.
5. Türkvatan A, Erden A, Türkoğlu MA, Yener Ö. Congenital variants and anomalies of the pancreas and pancreatic duct: imaging by magnetic resonance cholangiopancreatography and multidetector computed tomography. *Korean journal of radiology*. 2013 Dec 1;14(6):905-13.
6. Joseph P, Raju RS, Vyas FL, Eapen A, Sitaram V. Portal annular pancreas. A rare variant and a new classification. *JOP. Journal of the Pancreas*. 2010 Sep 6;11(5):453-5.
7. Luu AM, Braumann C, Herzog T, Janot M, Uhl W, Chromik AM. Circumportal Pancreas—a Must Know Pancreatic Anomaly for the Pancreatic Surgeon. *Journal of Gastrointestinal Surgery*. 2017 Feb;21(2):344-51.
8. Dhanapal B, Shankar G, Krishnaraj B, Govindarajalou R, Ruparelia J, Deivasigamani A, Sistla SC. Portal annular pancreas: case report of a rare anomaly. *Cureus*. 2018 Mar 26;10(3).
9. Harnoss JM, Harnoss JC, Diener MK, Contin P, Ulrich AB, Buechler MW, Schmitz-Winnenthal FH. Portal annular pancreas: a systematic review of a clinical challenge. *Pancreas*. 2014 Oct;43(7):981